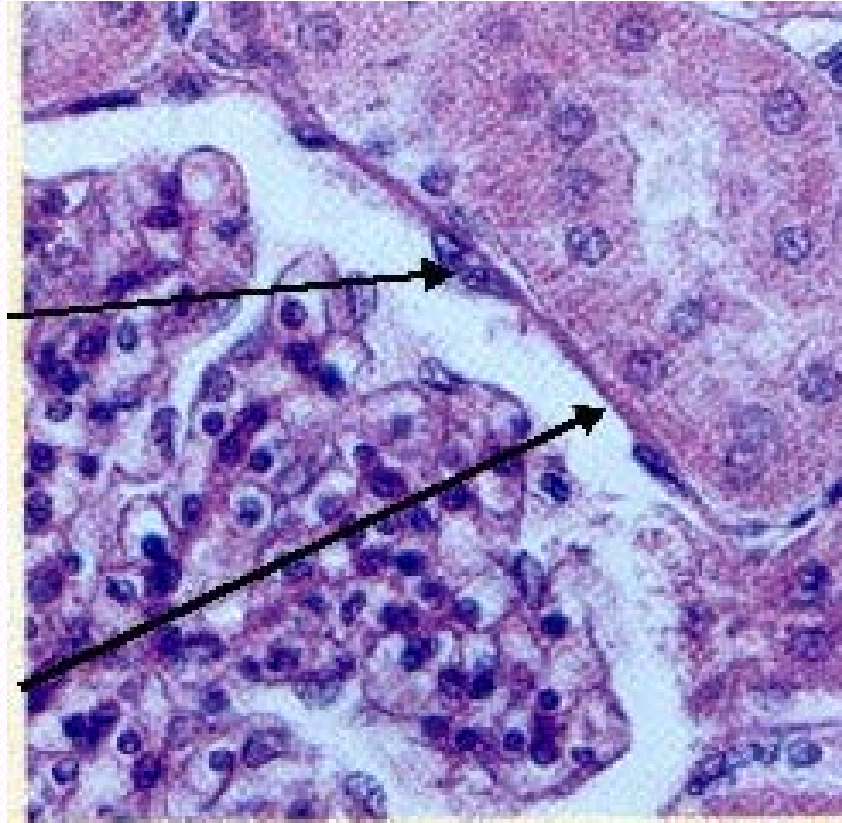


Press F5 to Start

Tissues & Histology Practice Lab Quiz

Press the down arrow key to get the answer and to go to next slide.

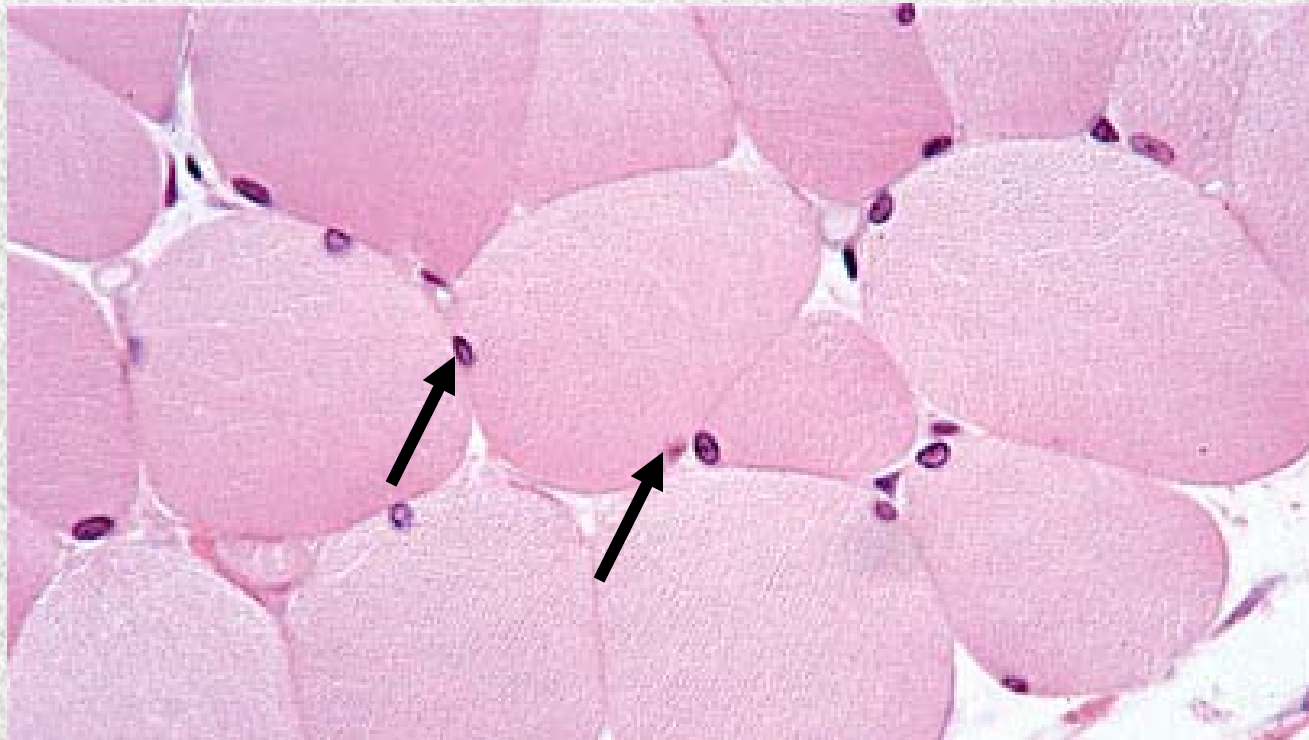
Identify the tissue type and its function.



Simple Squamous Epithelium

- Diffusion and Filtration
- Secretes lubricating substances in serosae

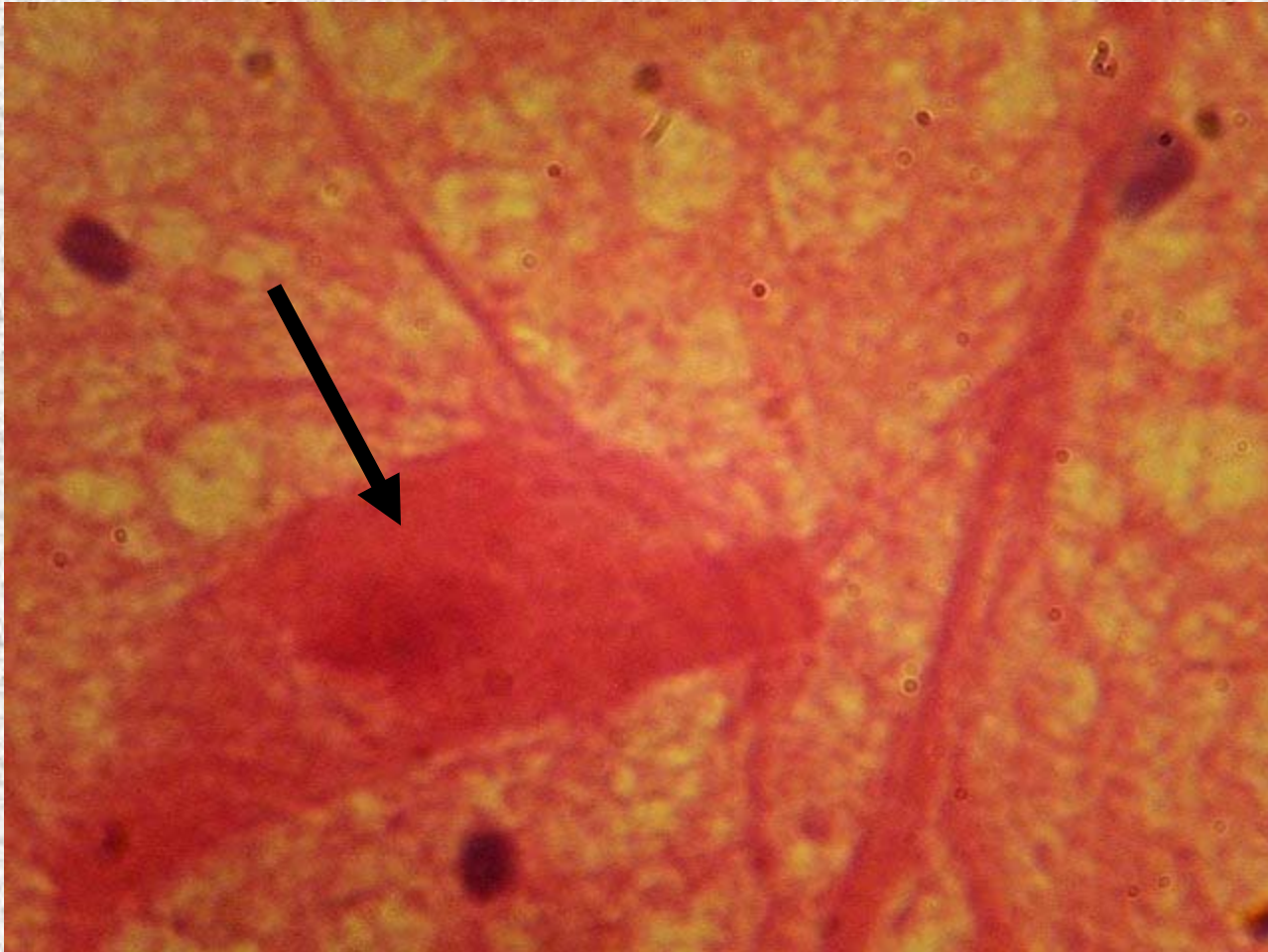Identify the structure indicated.



Skeletal Muscle

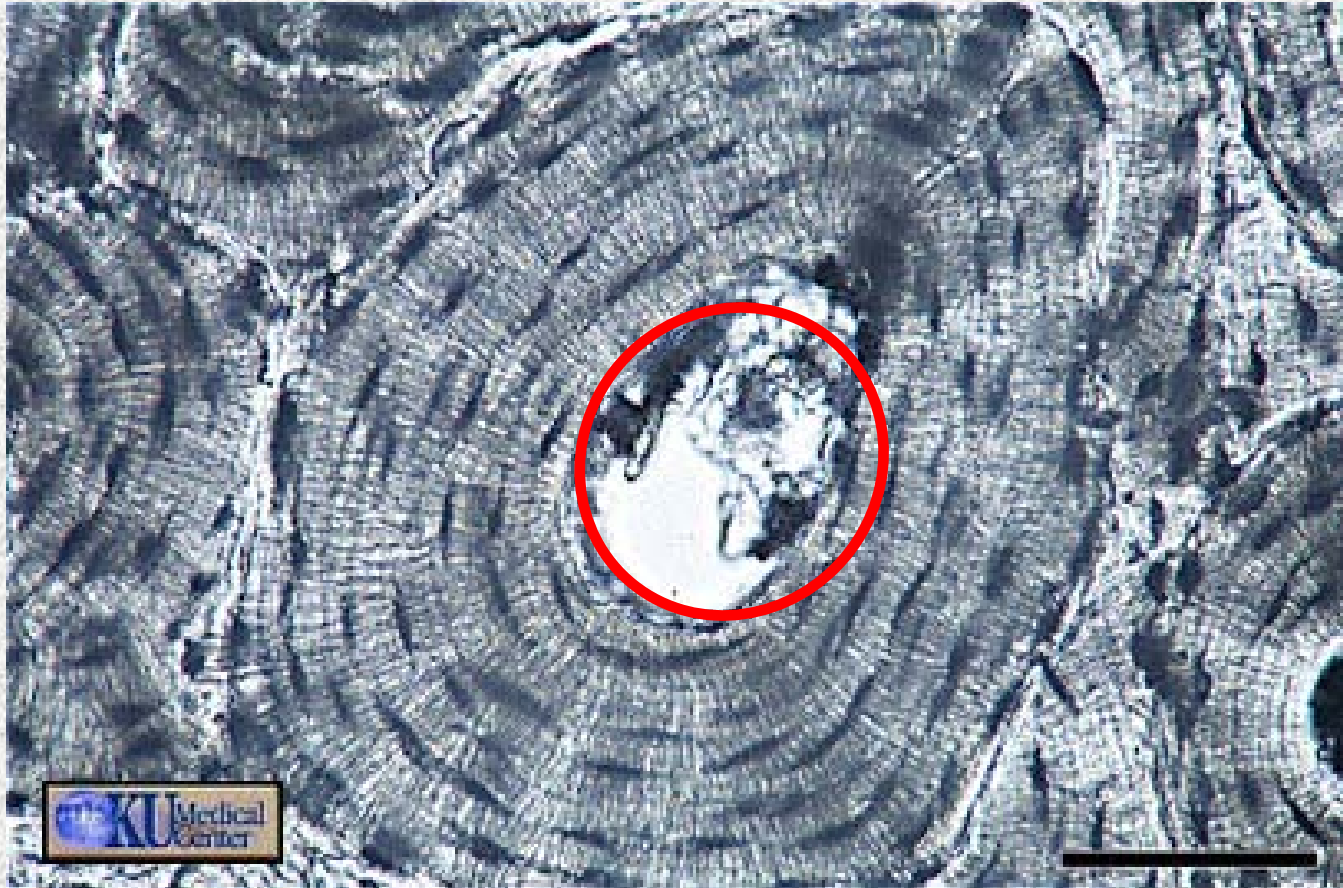
Multiple Peripherally Located Nuclei

Identify the structure indicated.



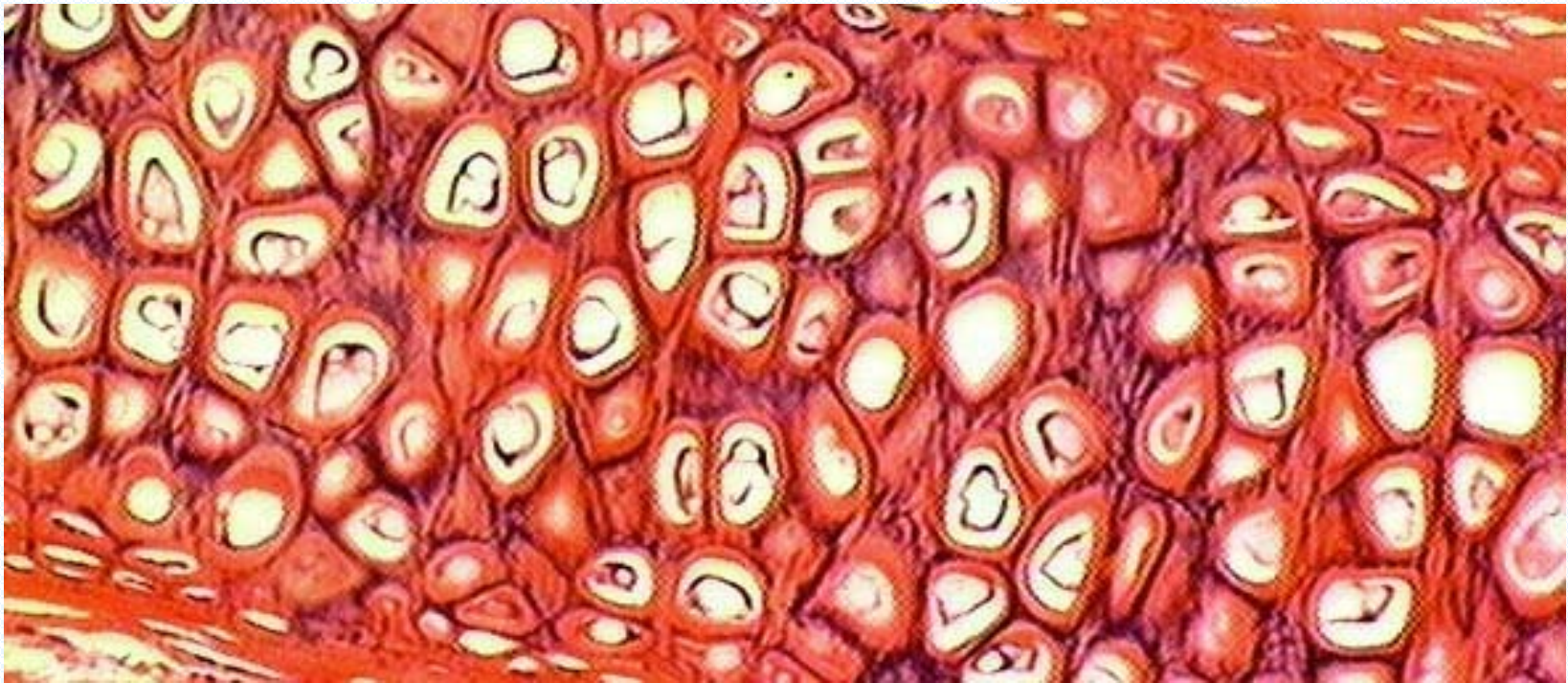Neuron Cell Body

Identify the structure indicated.



Compact Bone (Osseous Tissue)
Central Canal

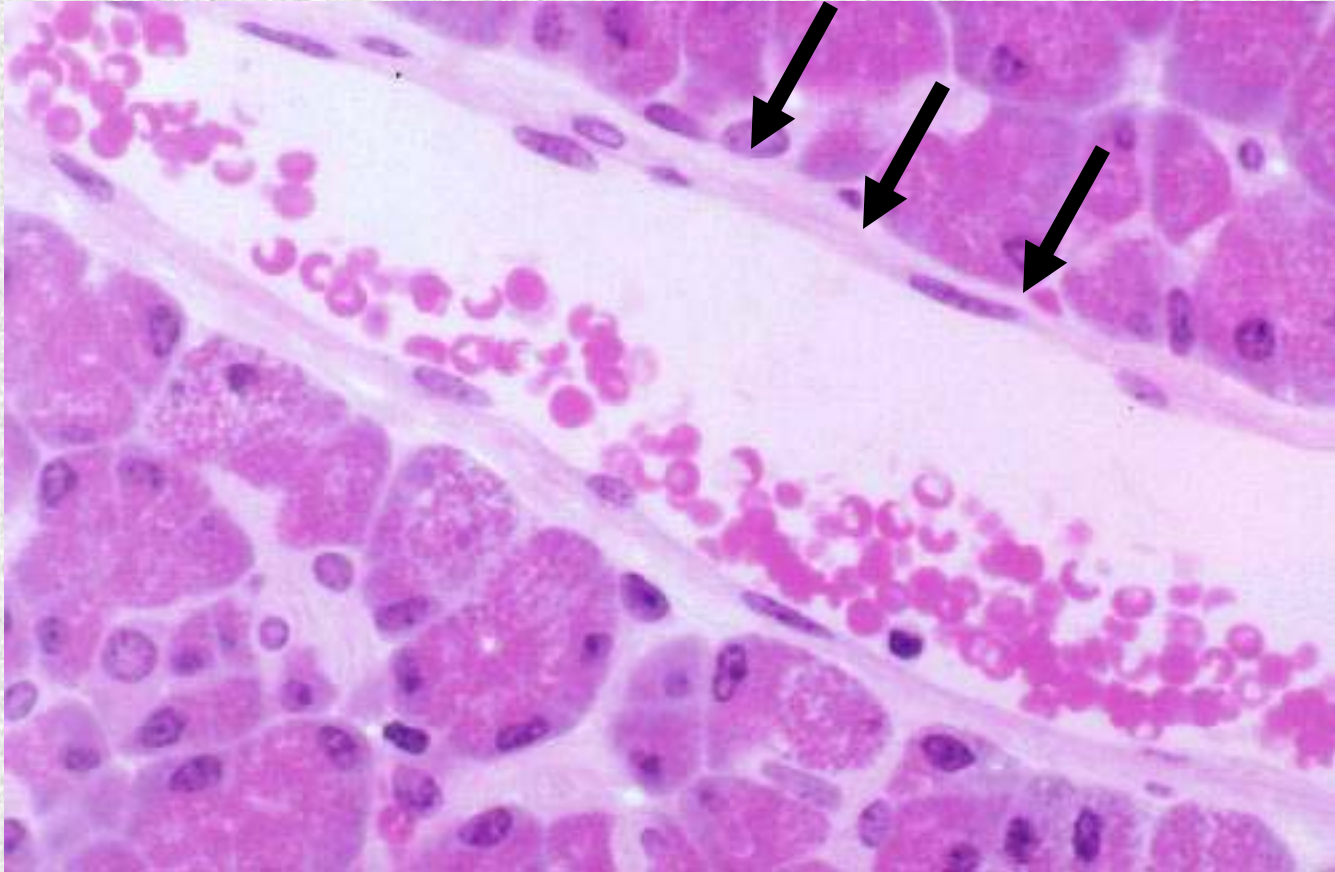
Identify the tissue type and a location where it is found.



Elastic Cartilage

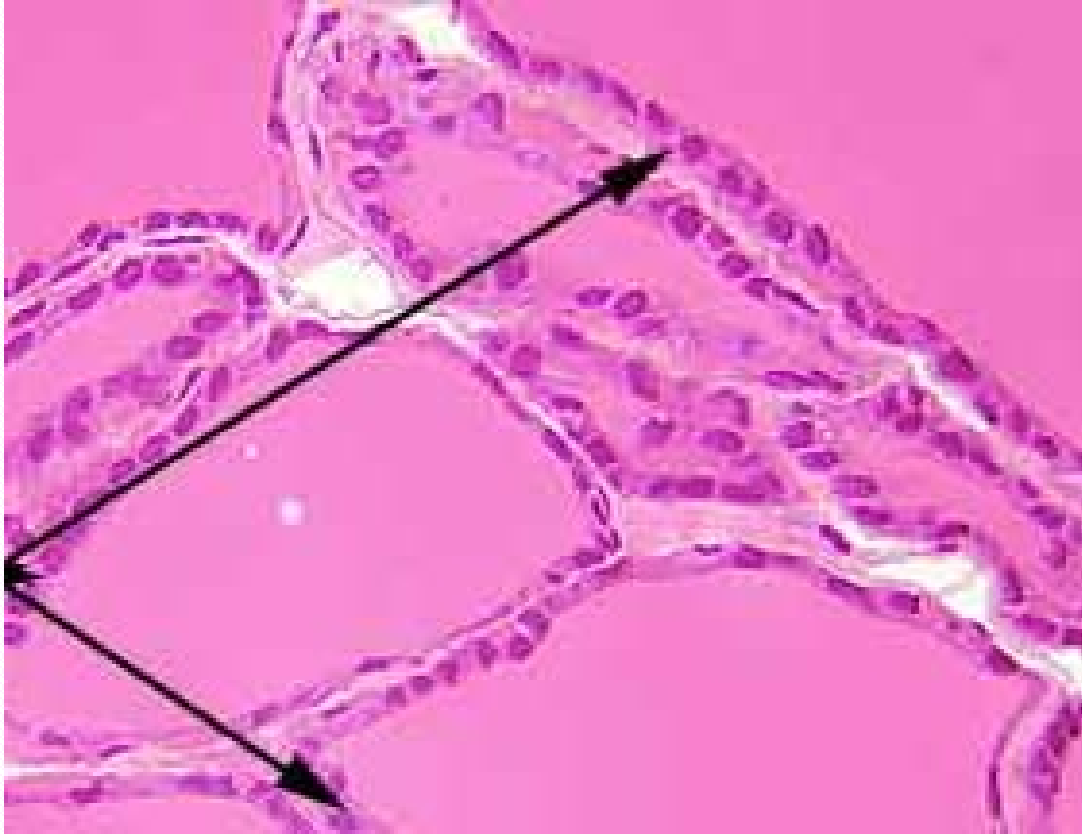- External Ear
- Epiglottis

Identify the structure indicated.



**Simple Squamous Epithelium:
Basement Membrane**

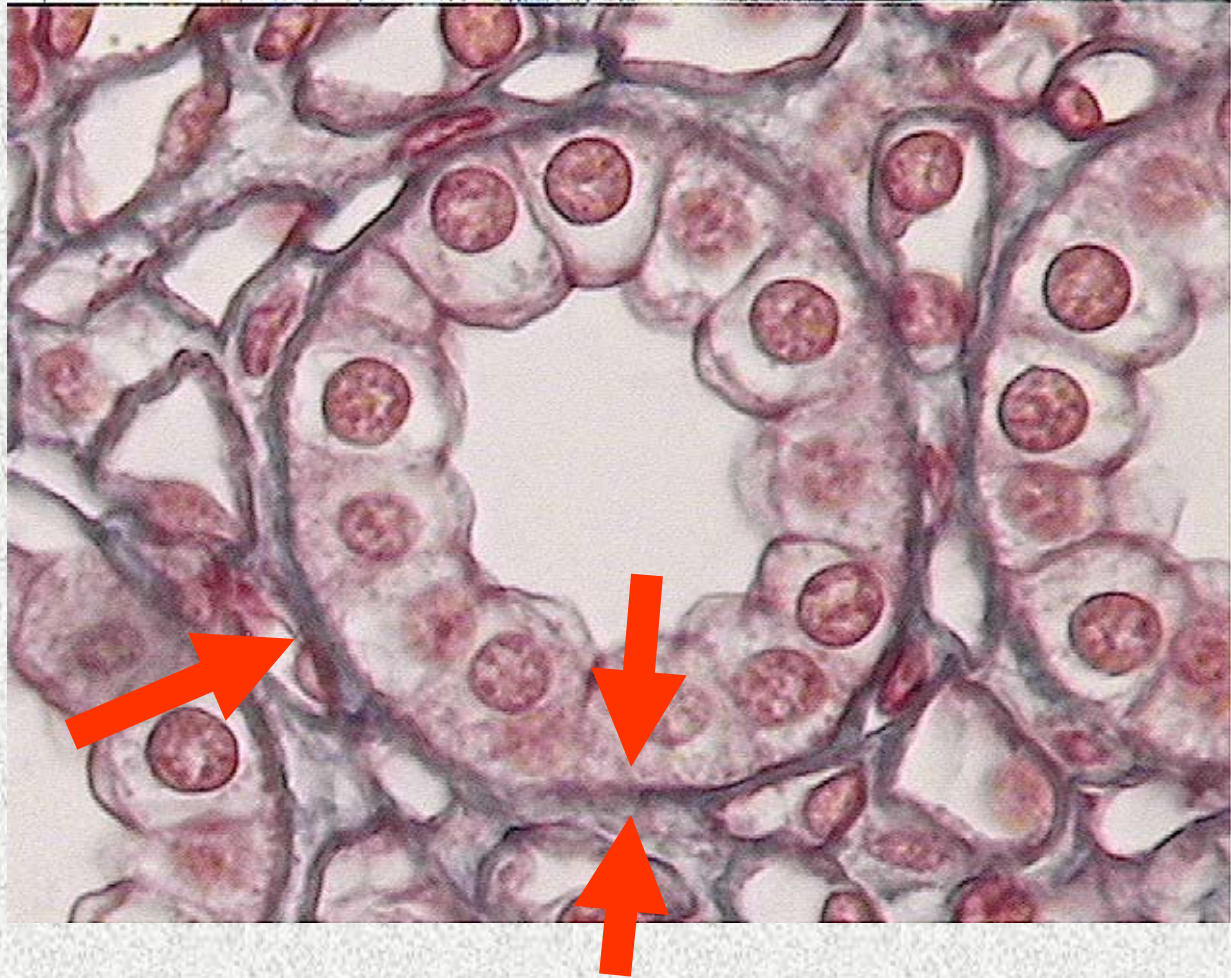Identify the tissue type and its function.



Simple Cuboidal Epithelium

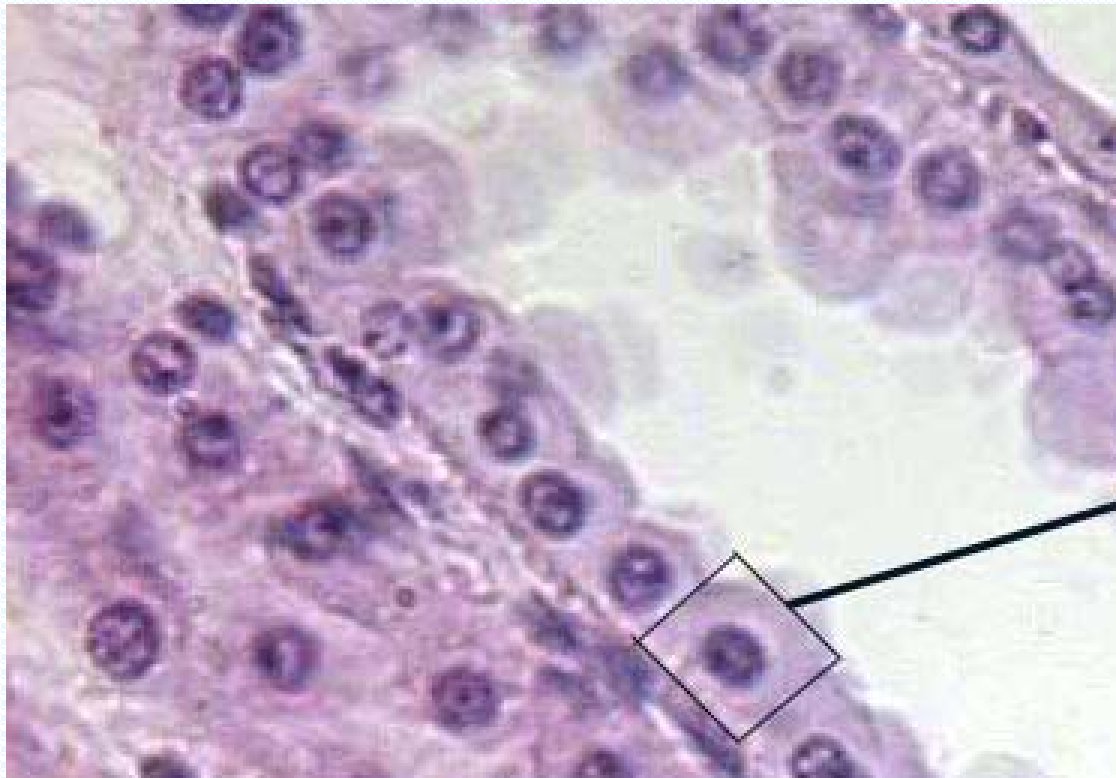
- Secretion
- Absorption

Identify the structure indicated.



Simple Cuboidal Epithelium
Basement Membrane

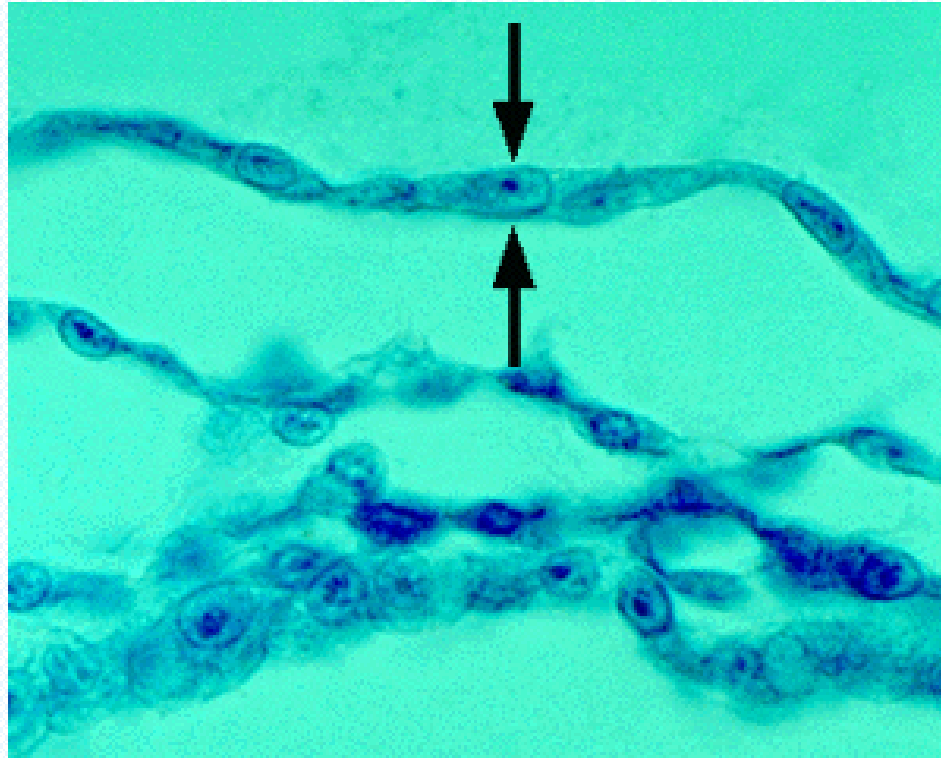
Identify the tissue type and a location where it is found.



Simple Cuboidal Epithelium

- Kidney tubules
- Ovary Surface
- Ducts and secretory portions of small glands

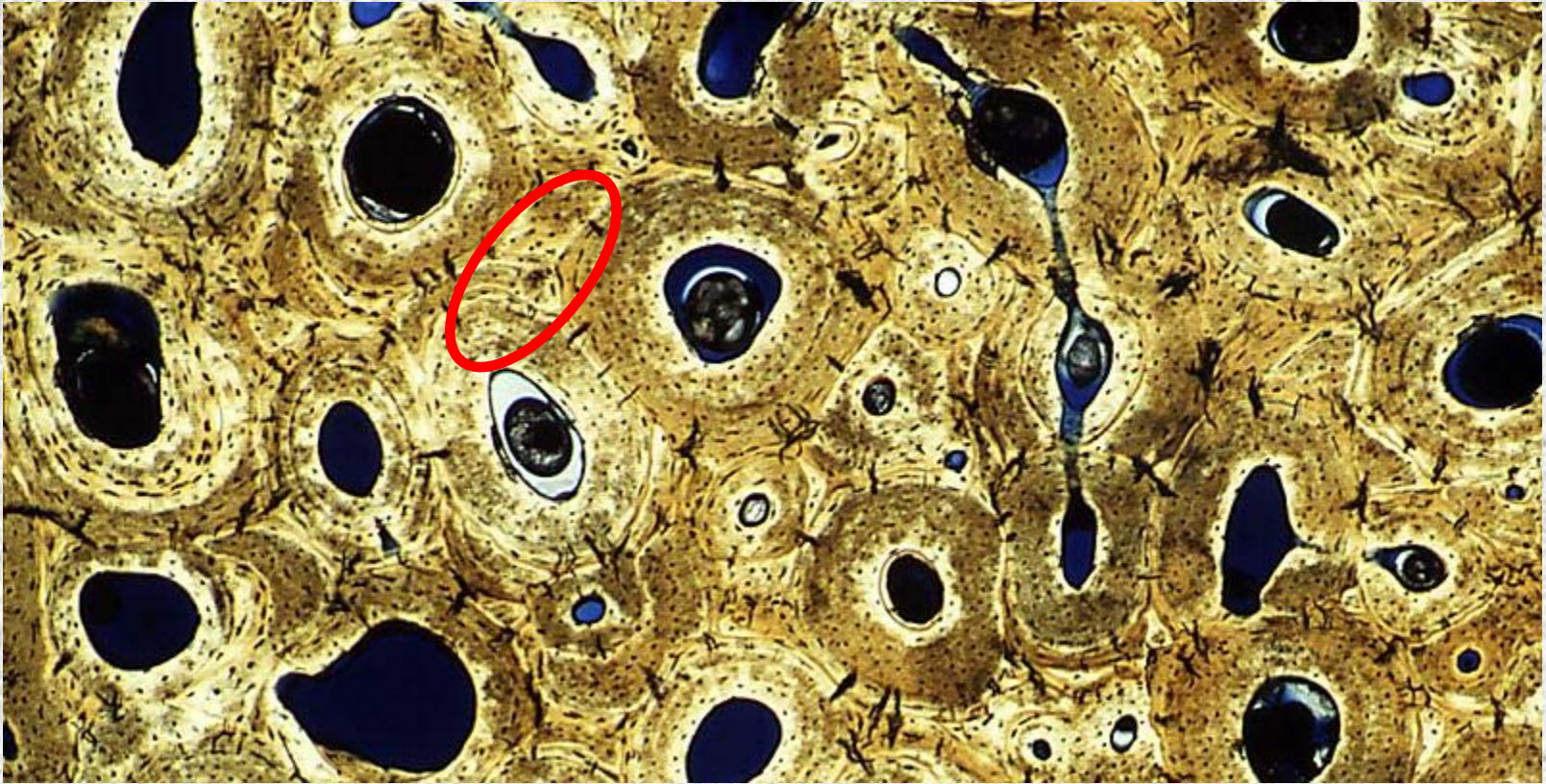
Identify the tissue type and a location where it is found.



Simple Squamous Epithelium

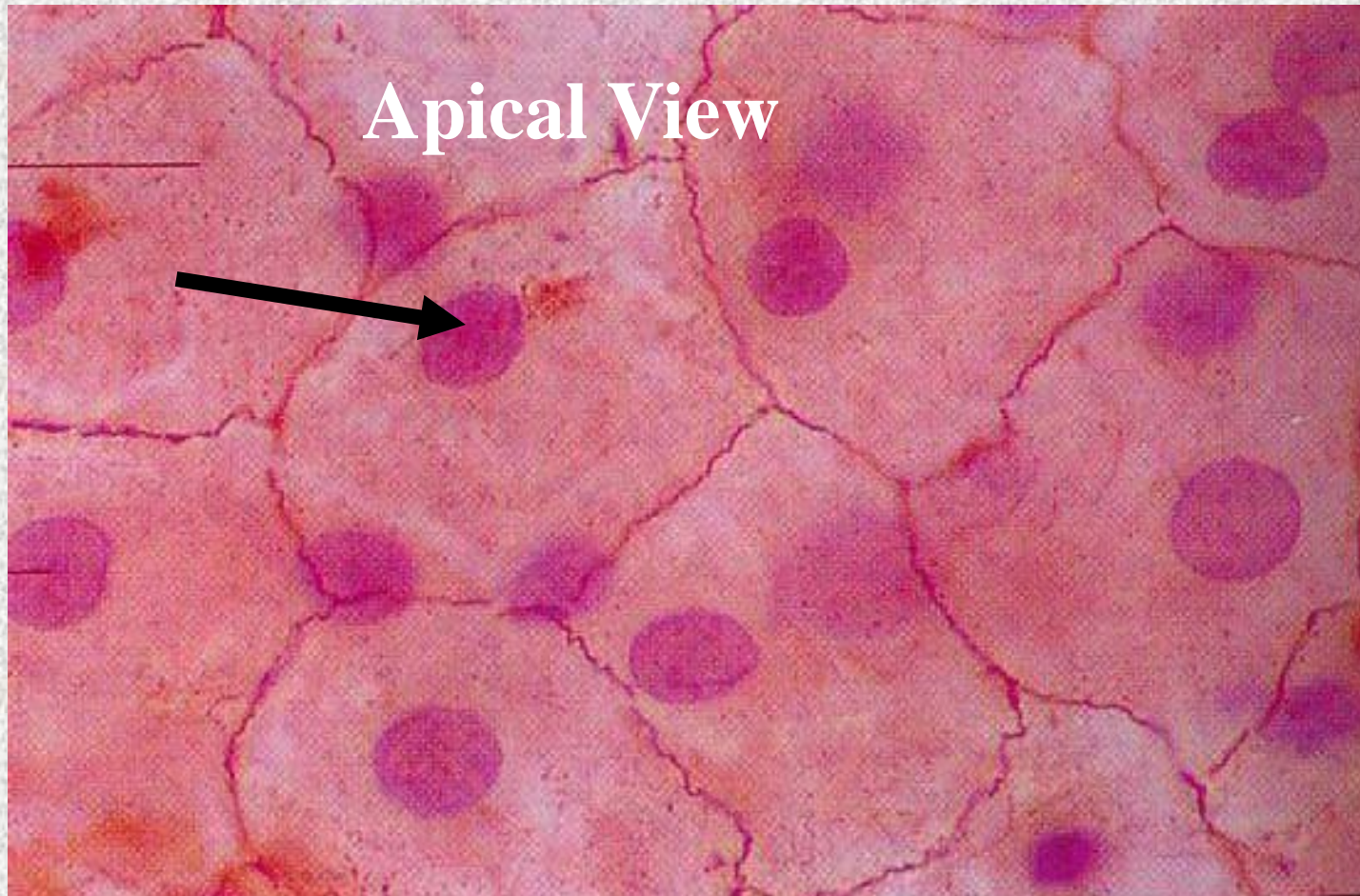
- Kidney glomeruli
- Air sacs of lungs
- Serosae
- Lining of heart, blood vessels and lymphatic vessels

Identify the structure indicated.



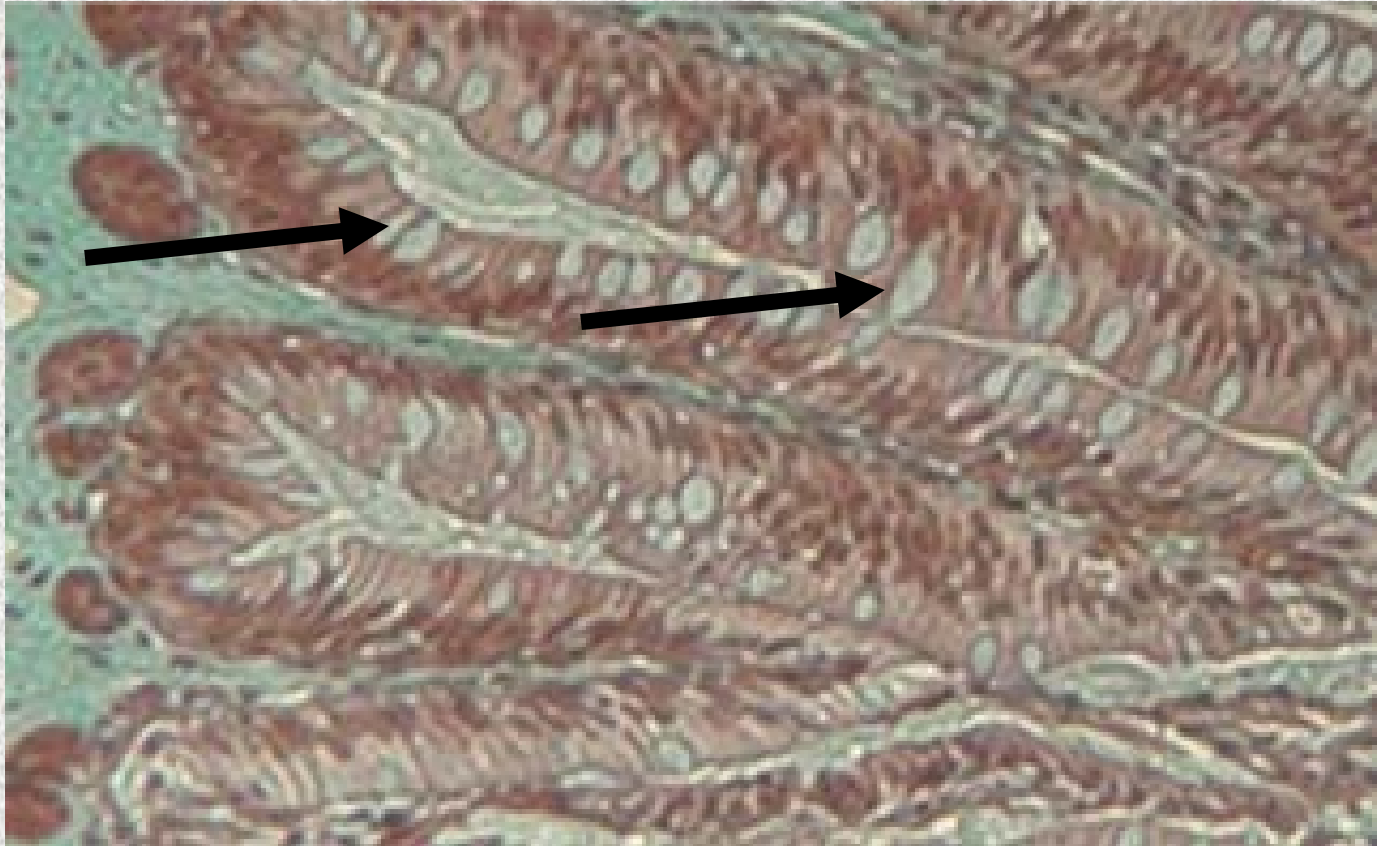
Compact Bone (Osseous Tissue)
Interstitial Lamellae

Identify the structure indicated.



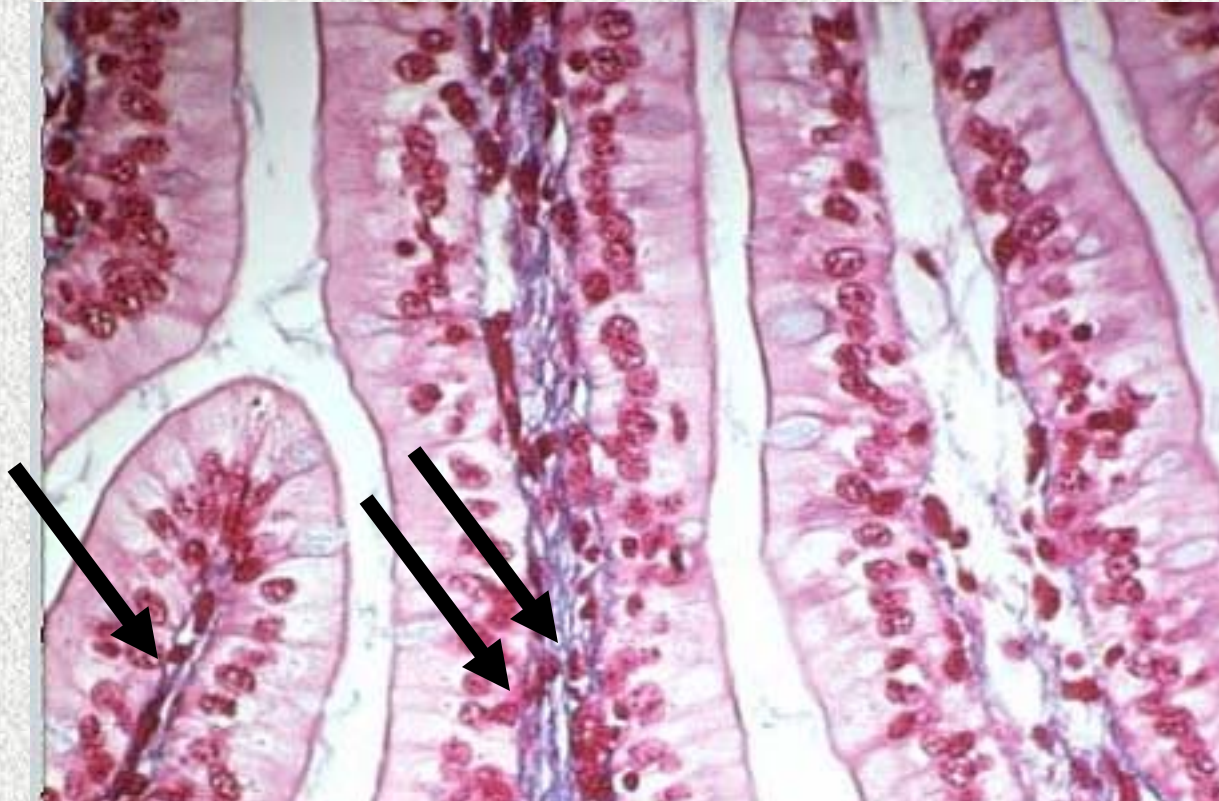
**Simple Squamous Epithelium:
Nucleus**

Identify the structure indicated.



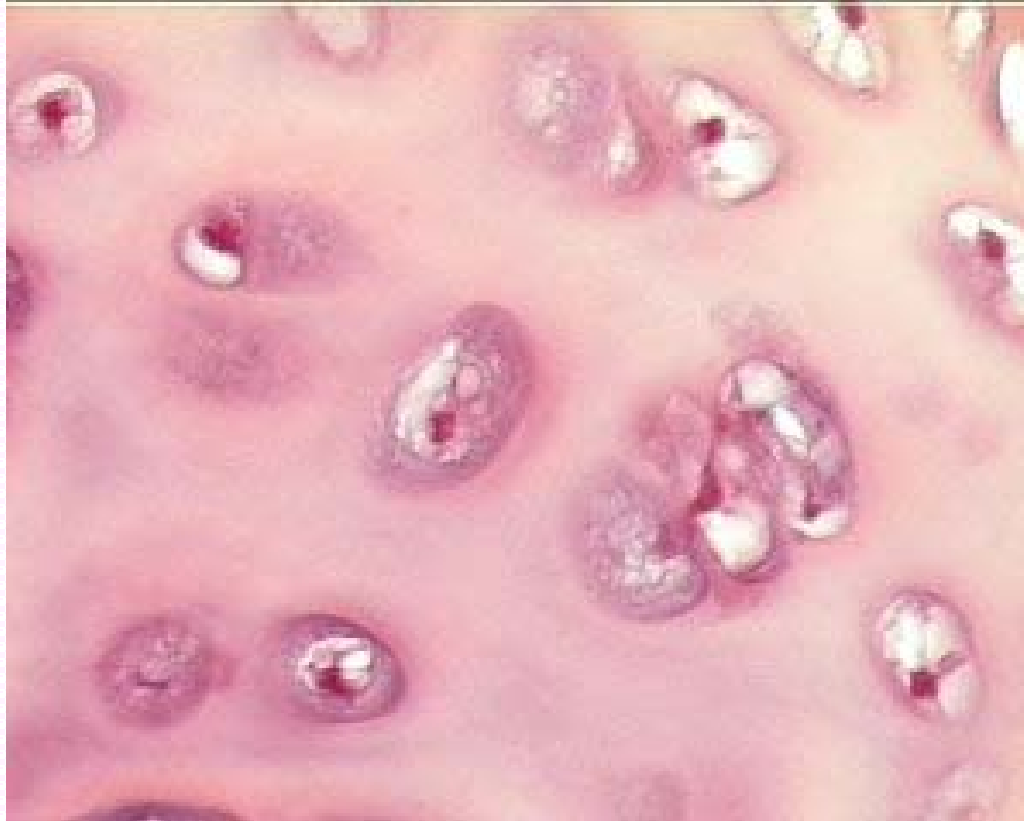
Nonciliated Simple Columnar Epithelium
Goblet Cell

Identify the structure indicated.



Nonciliated Simple Columnar Epithelium
Basement Membrane

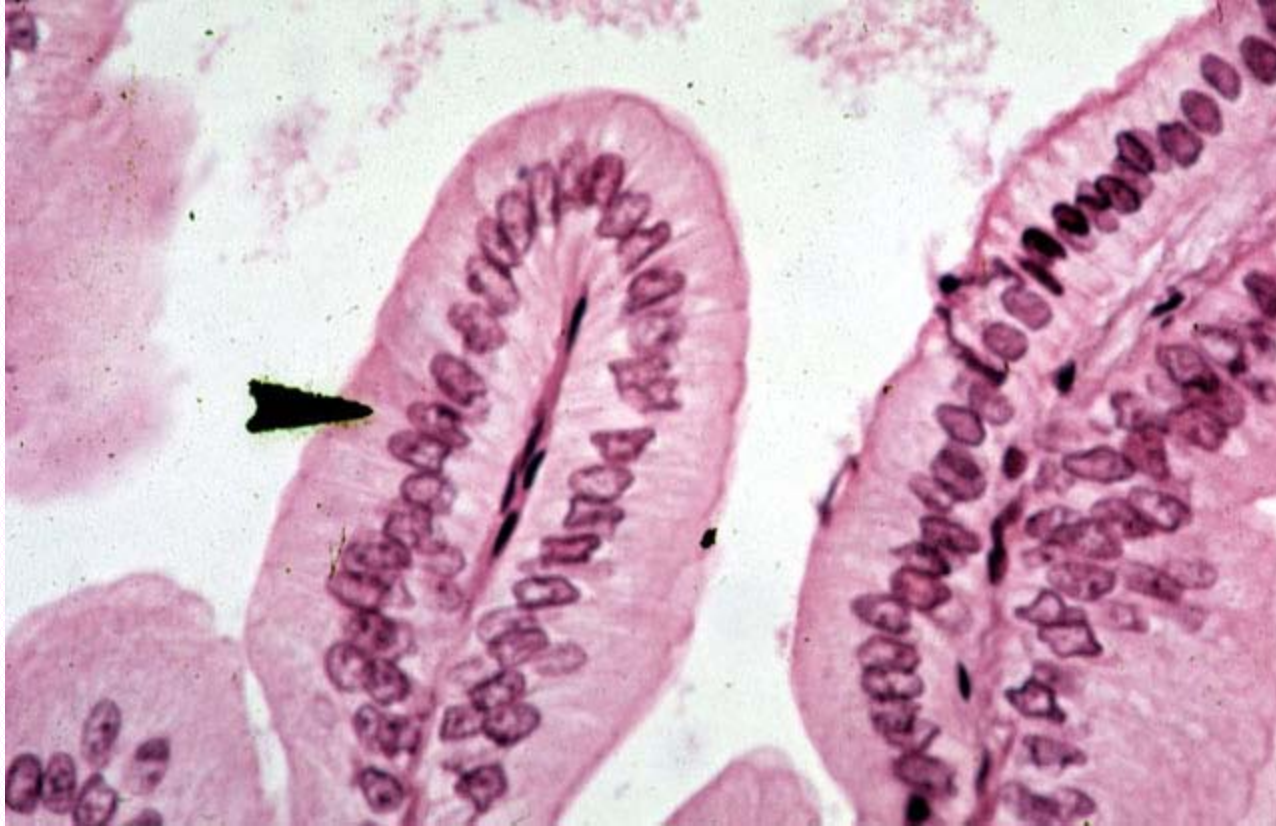Identify the tissue type and its function.



Hyaline Cartilage

- Supports and reinforces, resists compressive stress

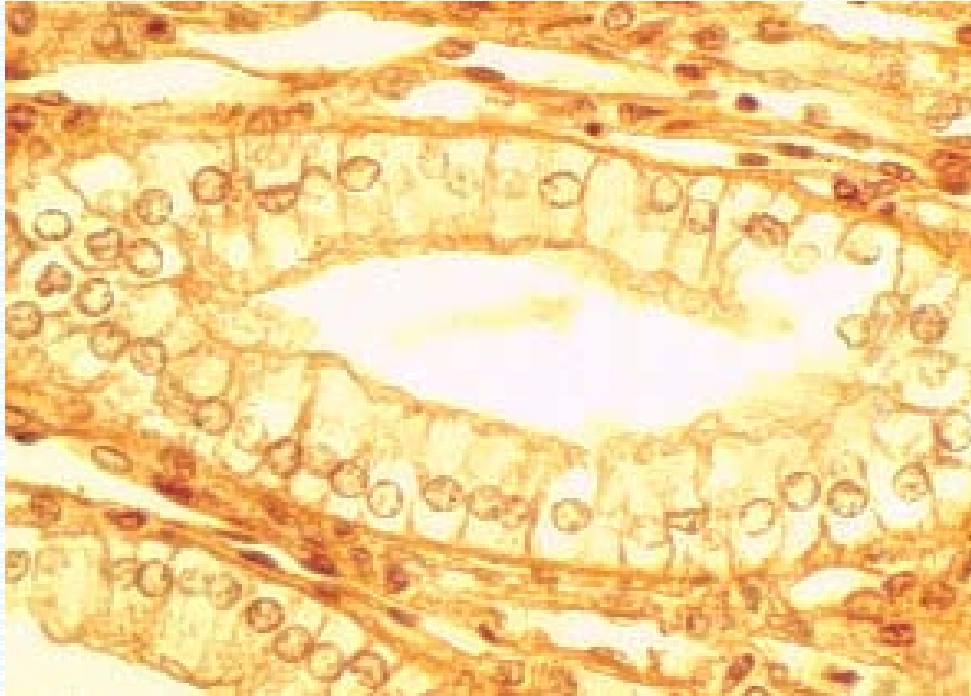
Identify the tissue type and its function.



Nonciliated Simple Columnar Epithelium

- Absorption
- Secretion of mucus, enzymes, and other substances

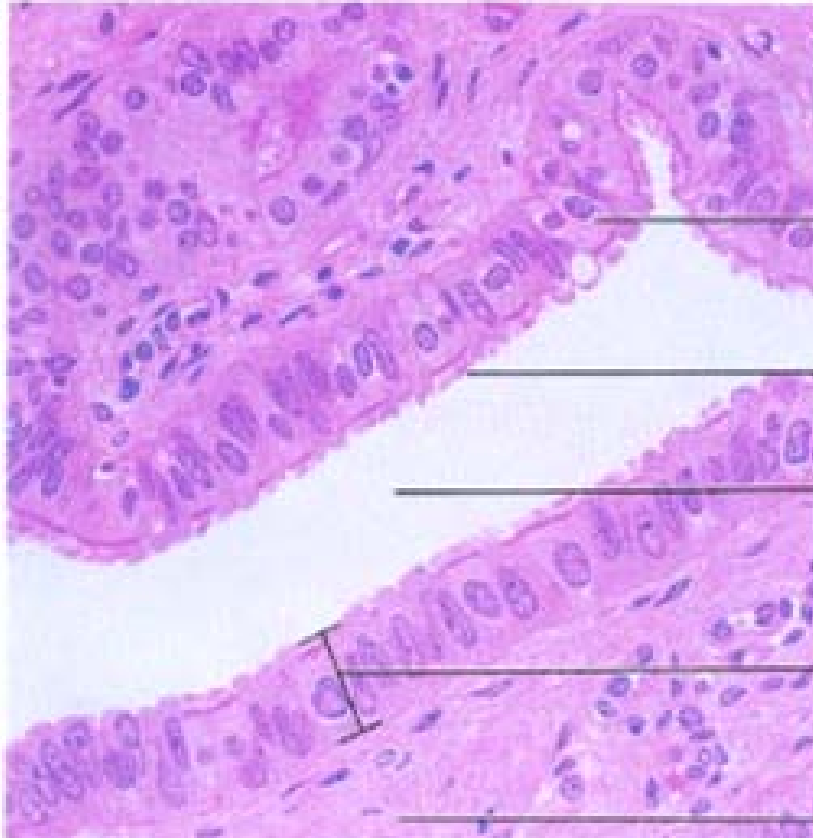
Identify the tissue type and a location where it is found.



Nonciliated Simple Columnar Epithelium

- Lines most of the digestive tract
- Excretory ducts of some glands

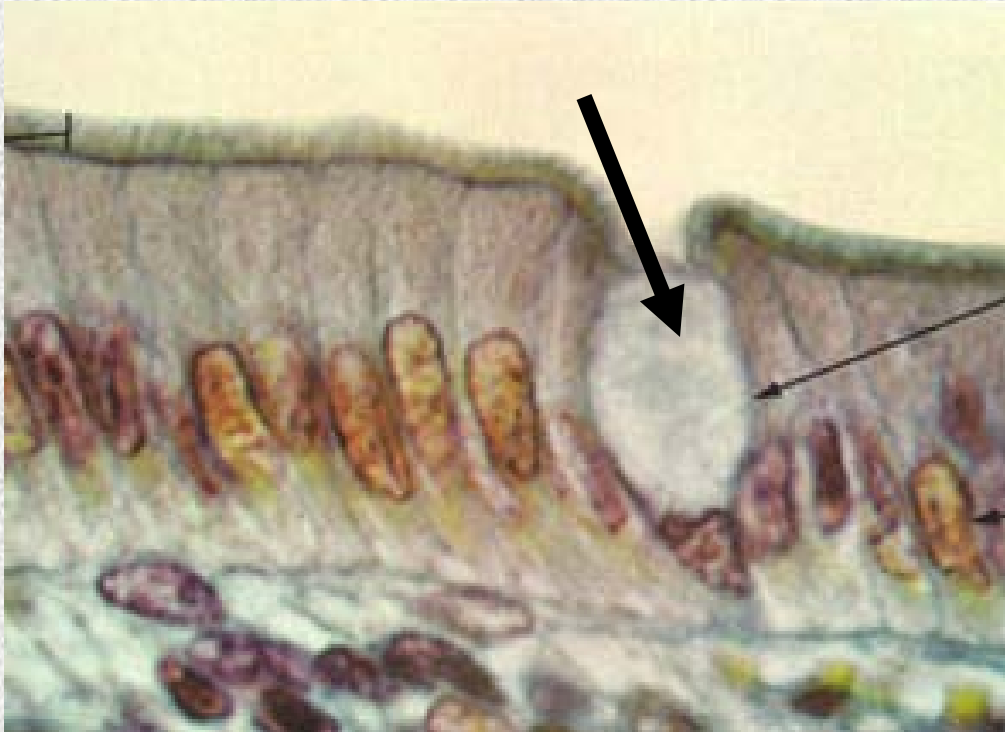
Identify the tissue type and its function.



Ciliated Simple Columnar Epithelium

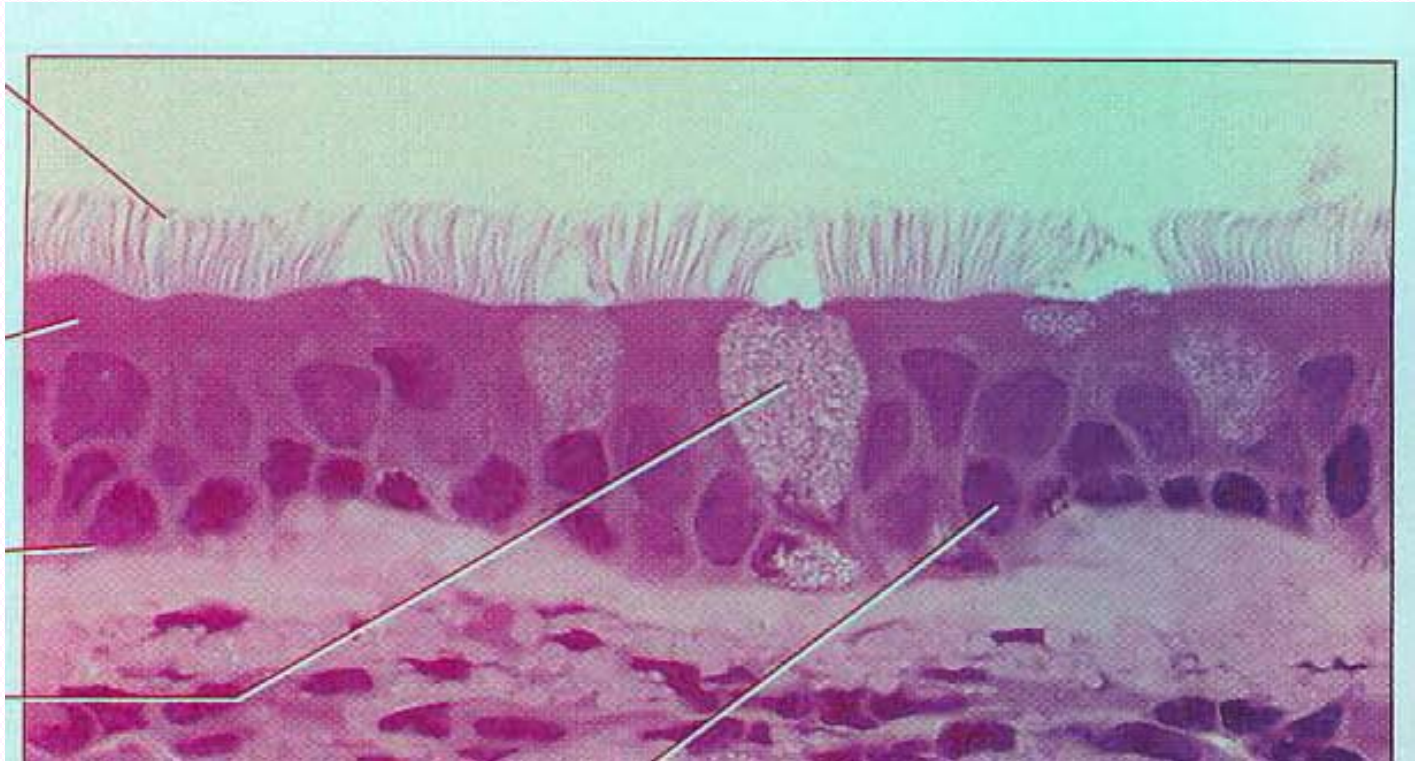
- Propels mucus by ciliary action
- Propels Ovum in the Fallopian tubes

Identify the structure indicated.



Ciliated Simple Columnar Epithelium
Goblet Cell

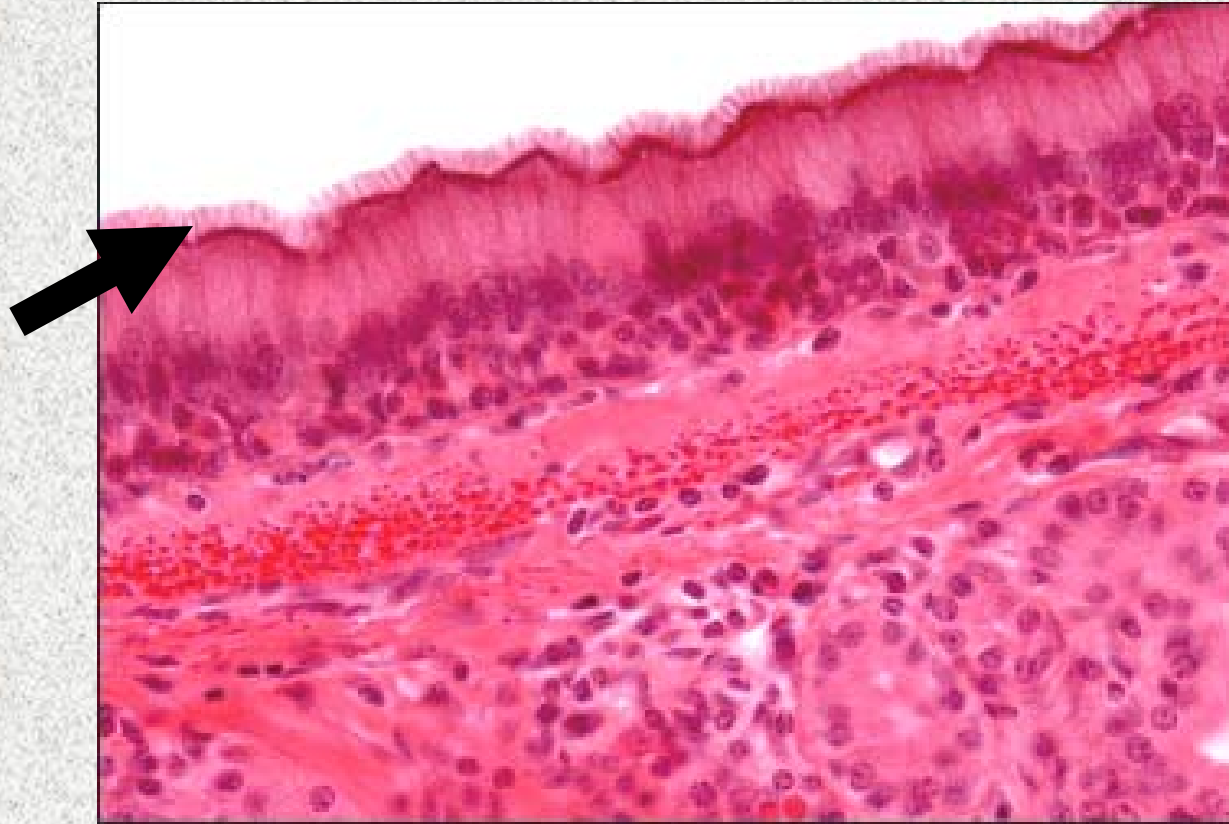
Identify the tissue type and its function.



Ciliated Pseudostratified Columnar Epithelium

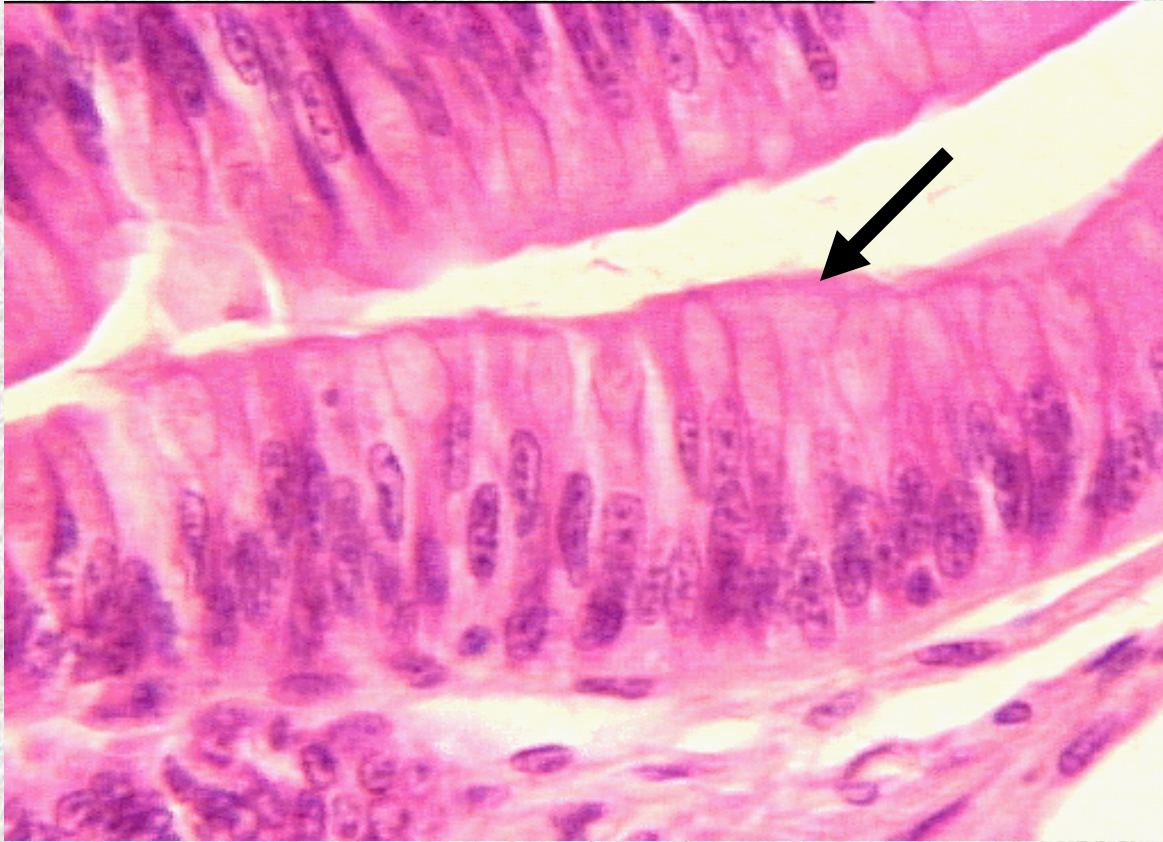
- Secretion of mucus
- Propels mucus by ciliary action

Identify the structure indicated.



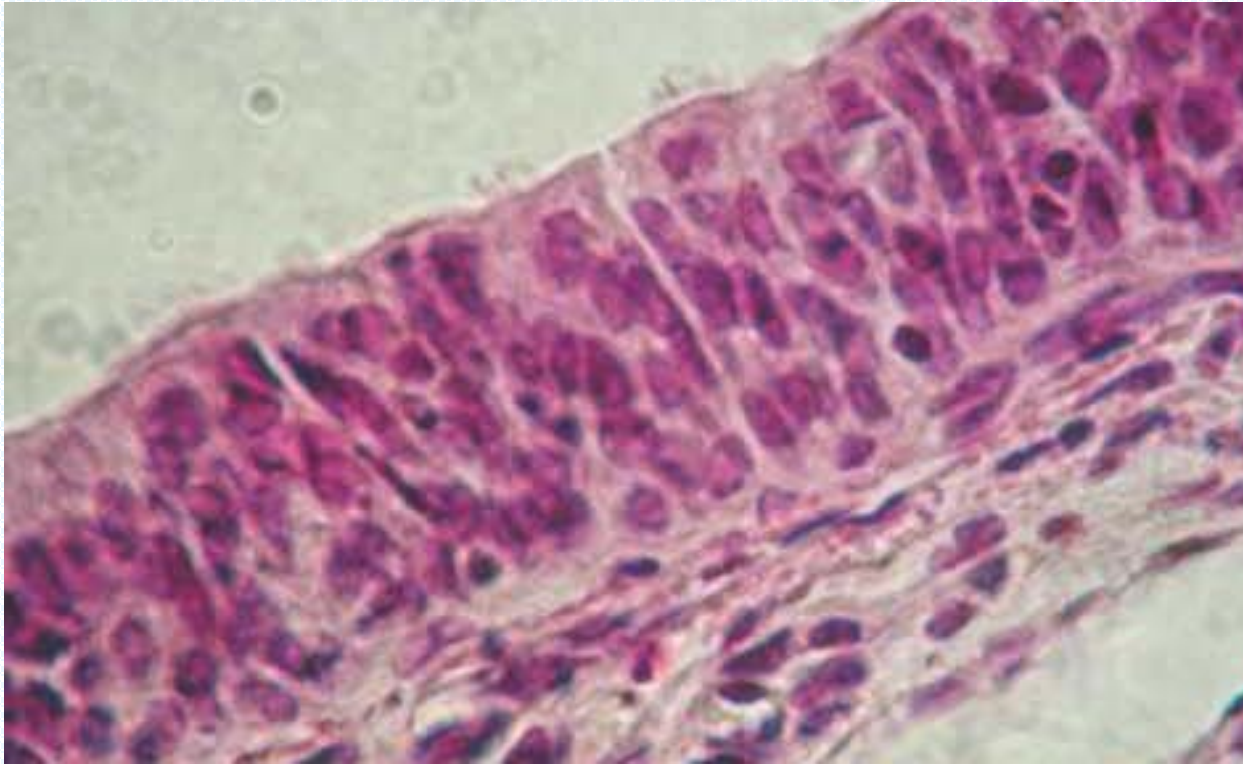
Ciliated Pseudostratified Columnar Epithelium
Cilia

Identify the structure indicated.



Pseudostratified Columnar Epithelium
Apical Surface

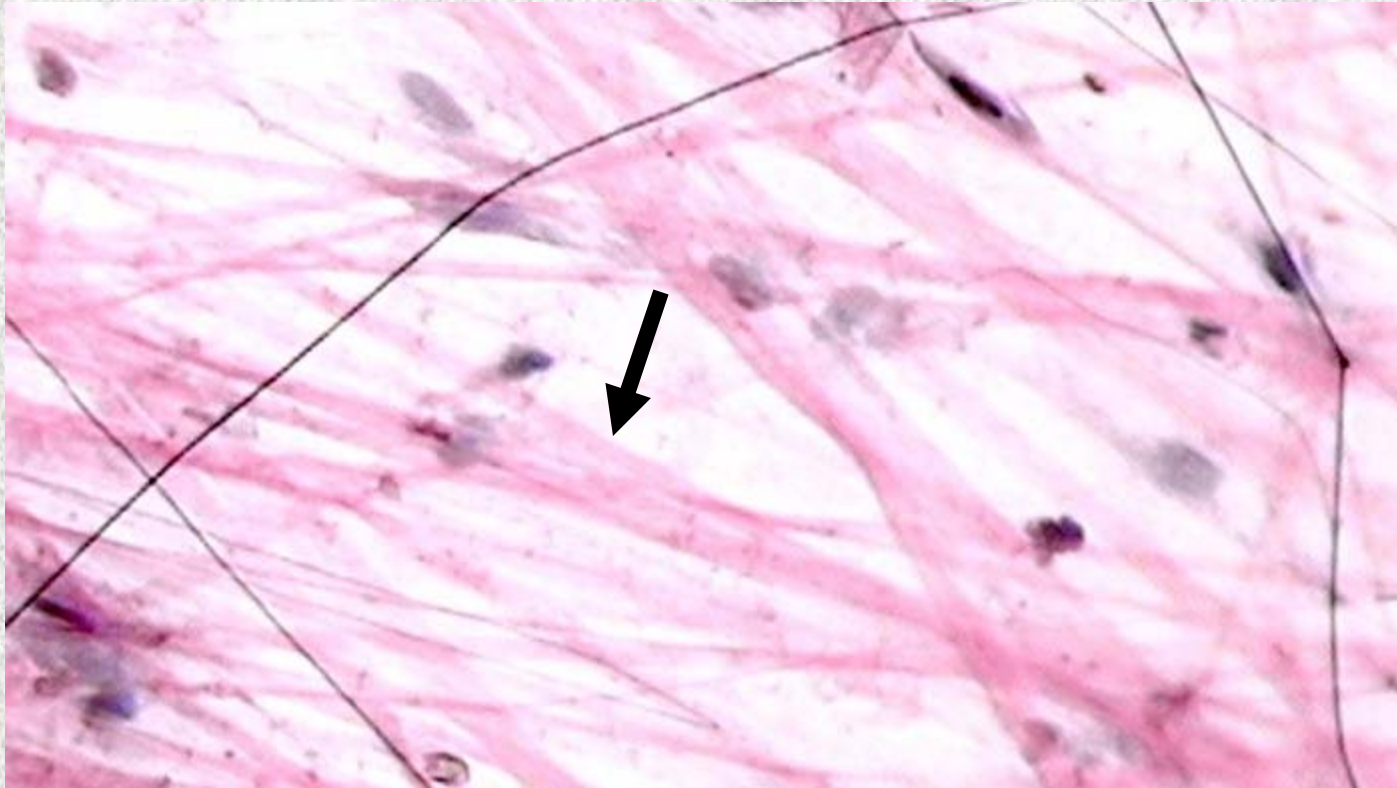
Identify the tissue type and a location where it is found.



Pseudostratified Columnar Epithelium

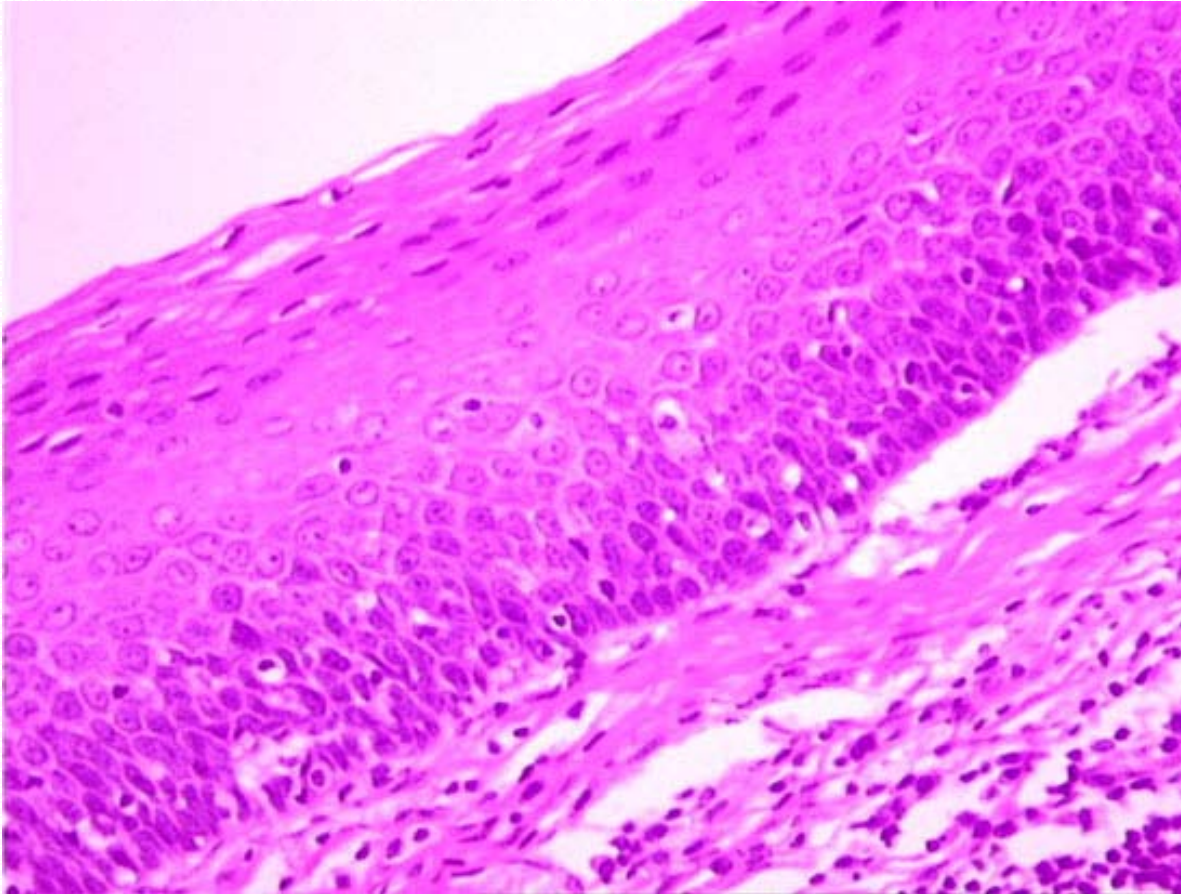
- Ducts of large glands
- Male's sperm-carrying ducts

Identify the structure indicated.



Loose Areolar Connective Tissue
Collagen Fiber

Identify the tissue type and its function.

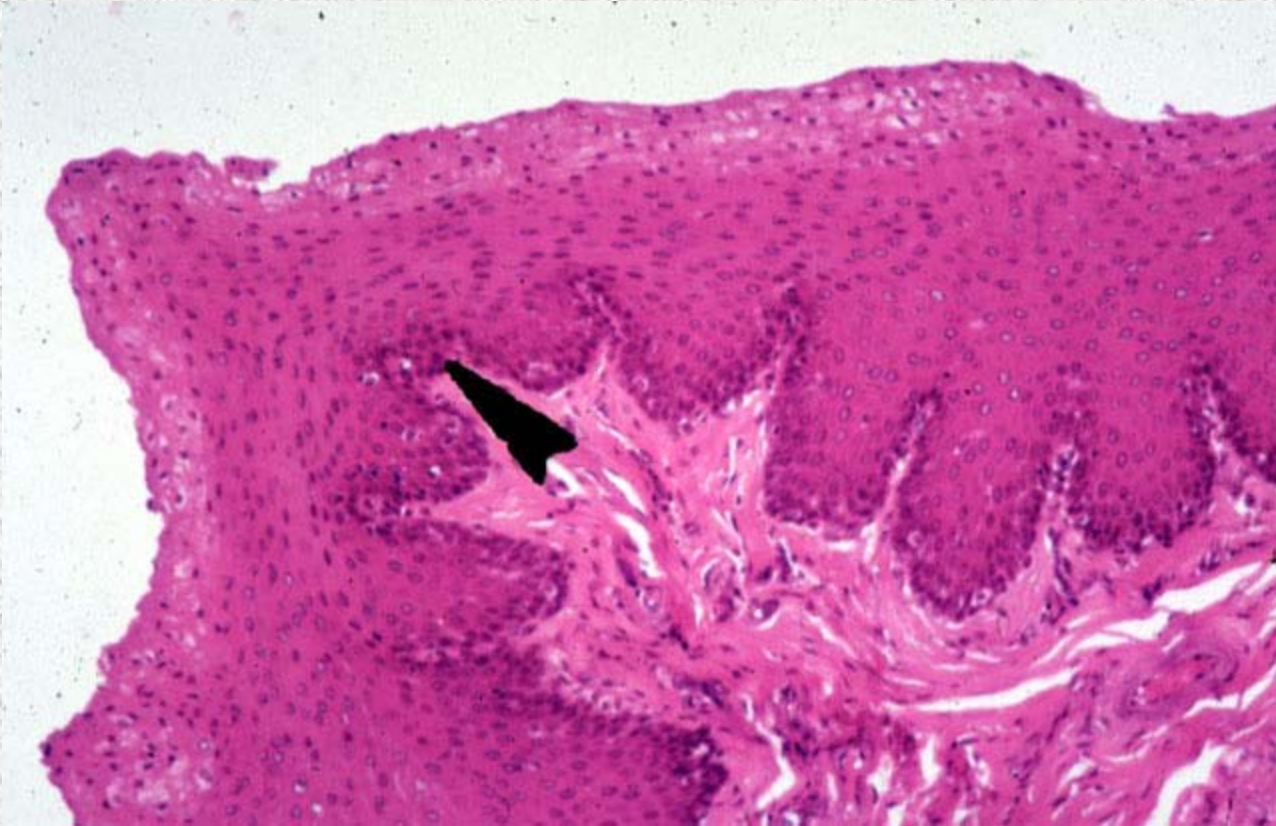


Non-Keratinized Stratified Squamous

- Protects underlying tissues in areas subjected to abrasion

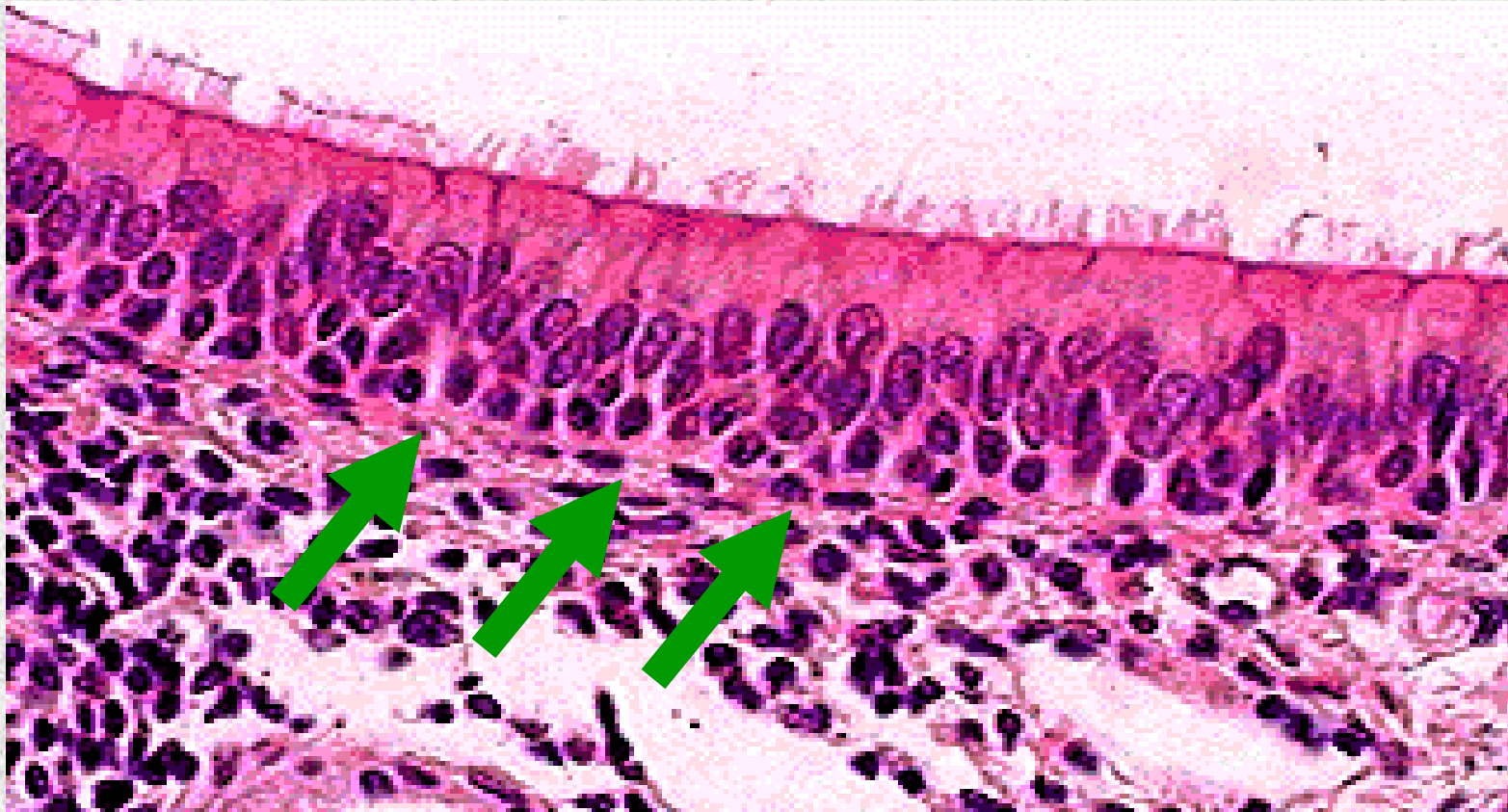
Epithelium

Identify the structure indicated.



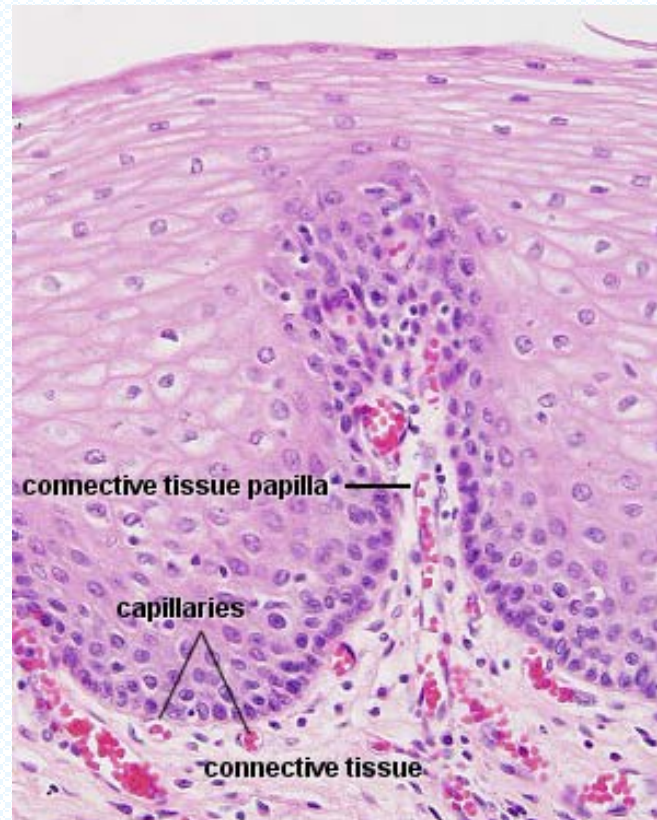
Non-Keratinized Stratified Squamous Epithelium

Identify the structure indicated.



Ciliated Pseudostratified Columnar Epithelium
Basement membrane

Identify the tissue type and a location where it is found.

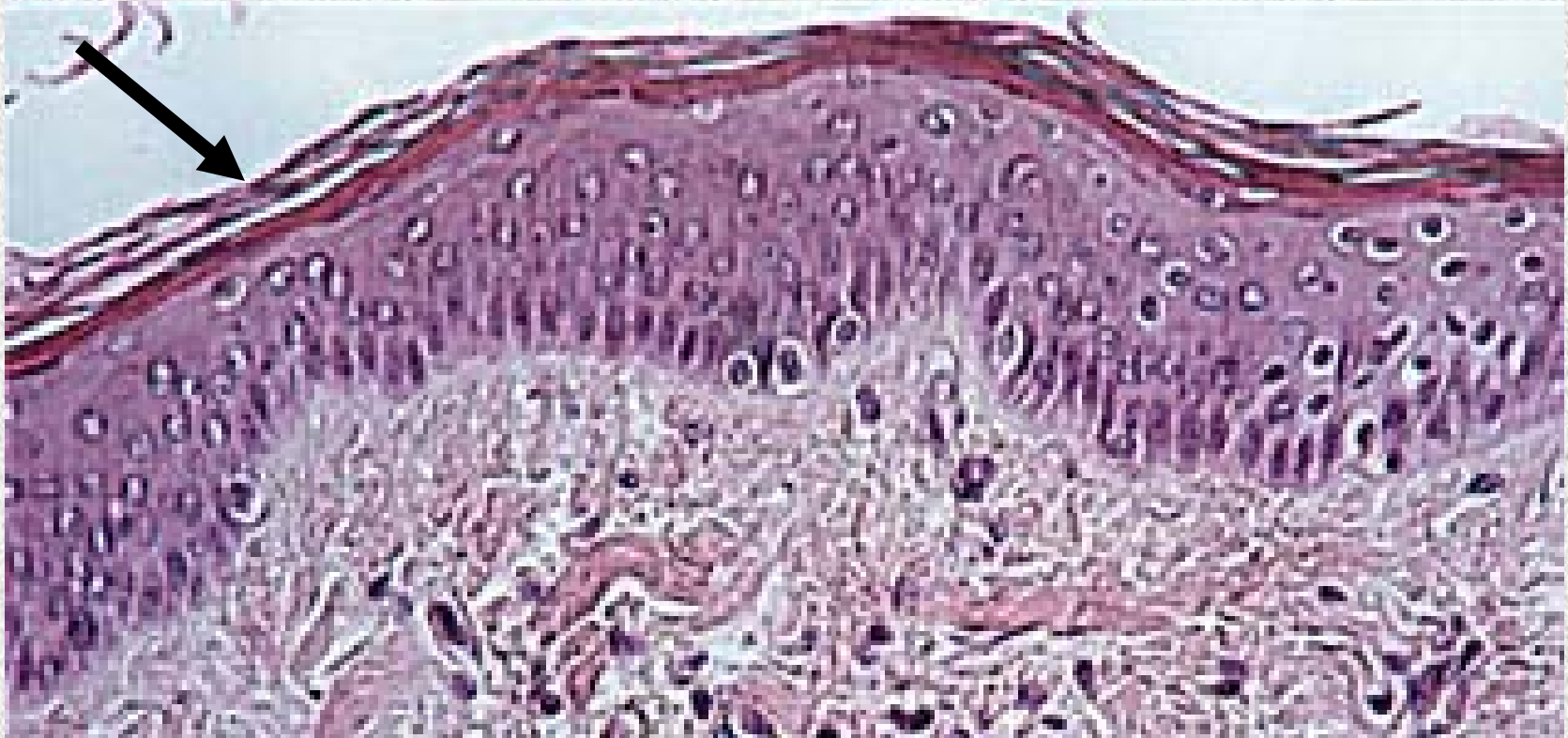


Non-Keratinized Stratified Squamous

- Esophagus
- Mouth
- Vagina

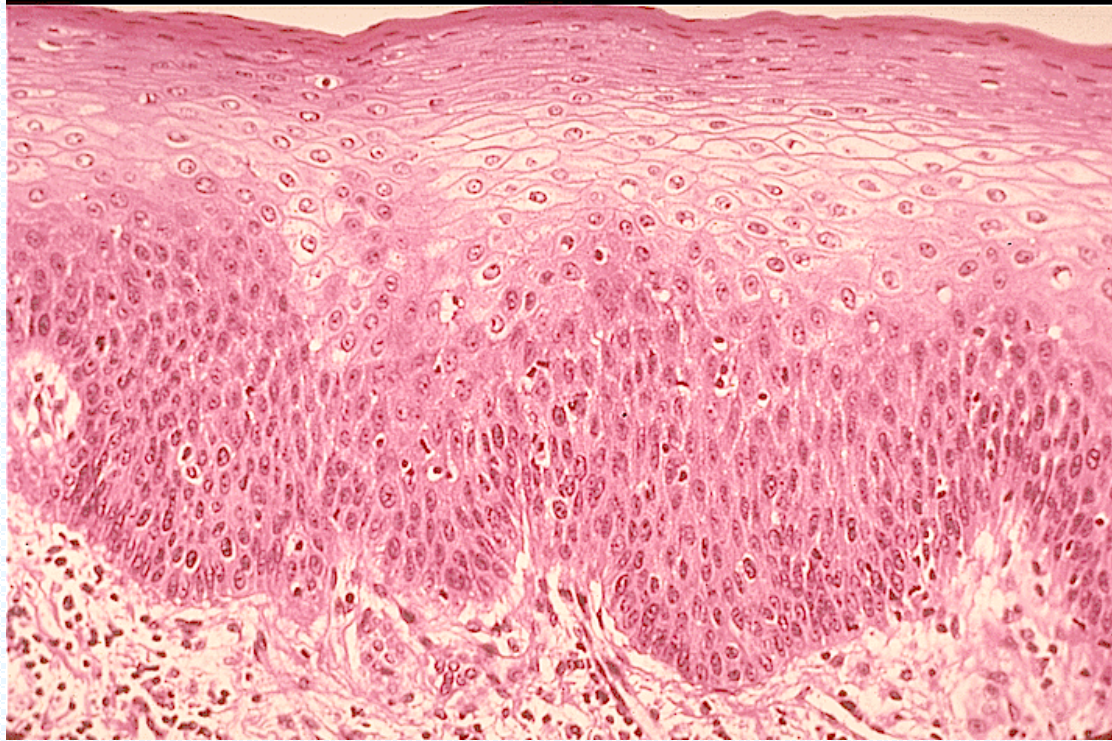
Epithelium

Identify the structure indicated.



Keratinized Stratified Squamous Epithelium

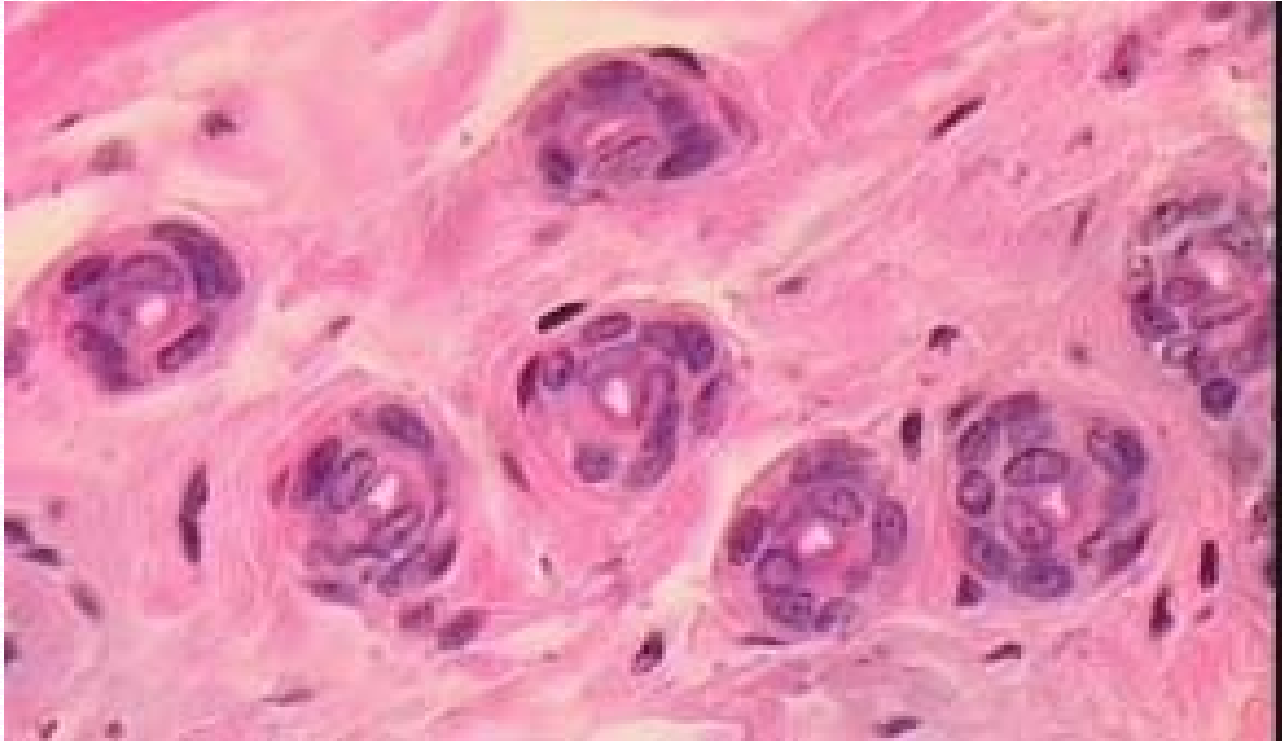
Identify the tissue type and a location where it is found.



Keratinized Stratified Squamous Epithelium

•Epidermis of skin

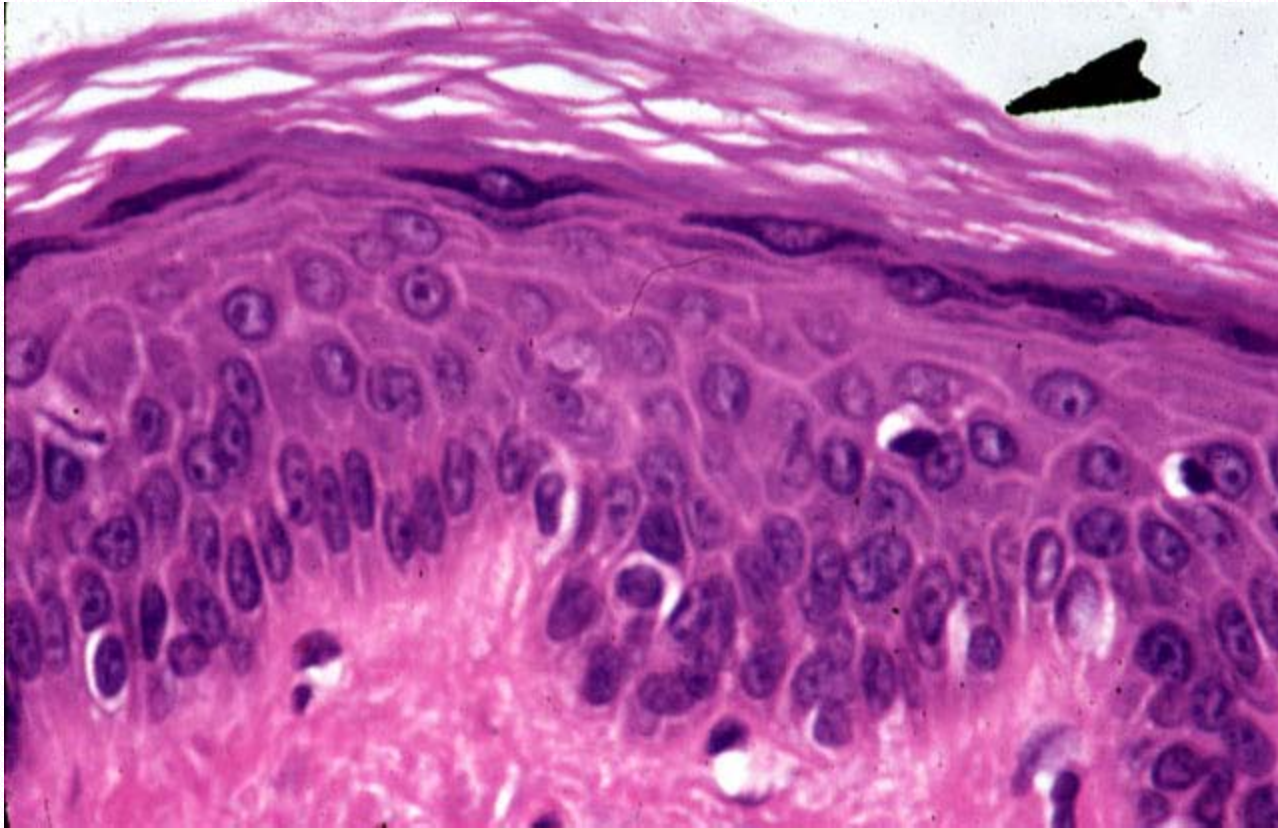
Identify the tissue type and its function.



Stratified Cuboidal Epithelium

- Protection and limited secretion and absorption

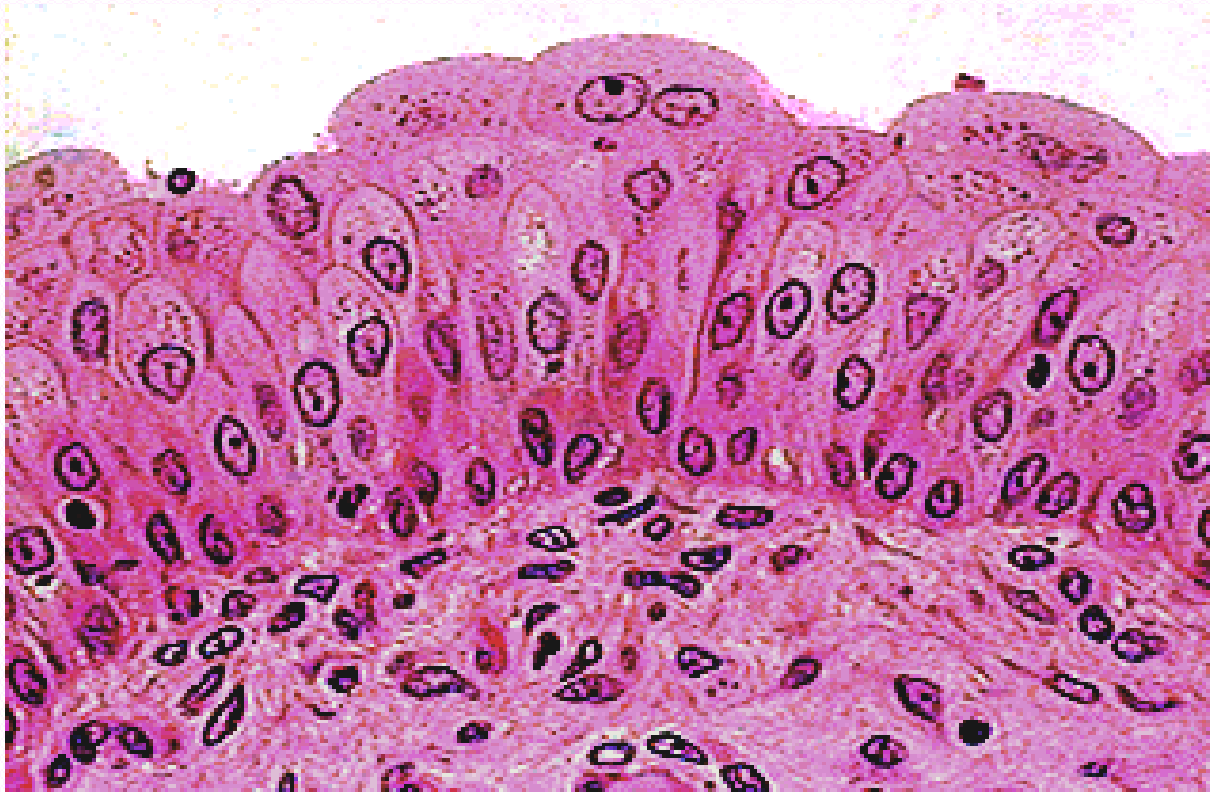
Identify the tissue type and its function.



Keratinized Stratified Squamous Epithelium

- Protects underlying tissues in areas subjected to abrasion

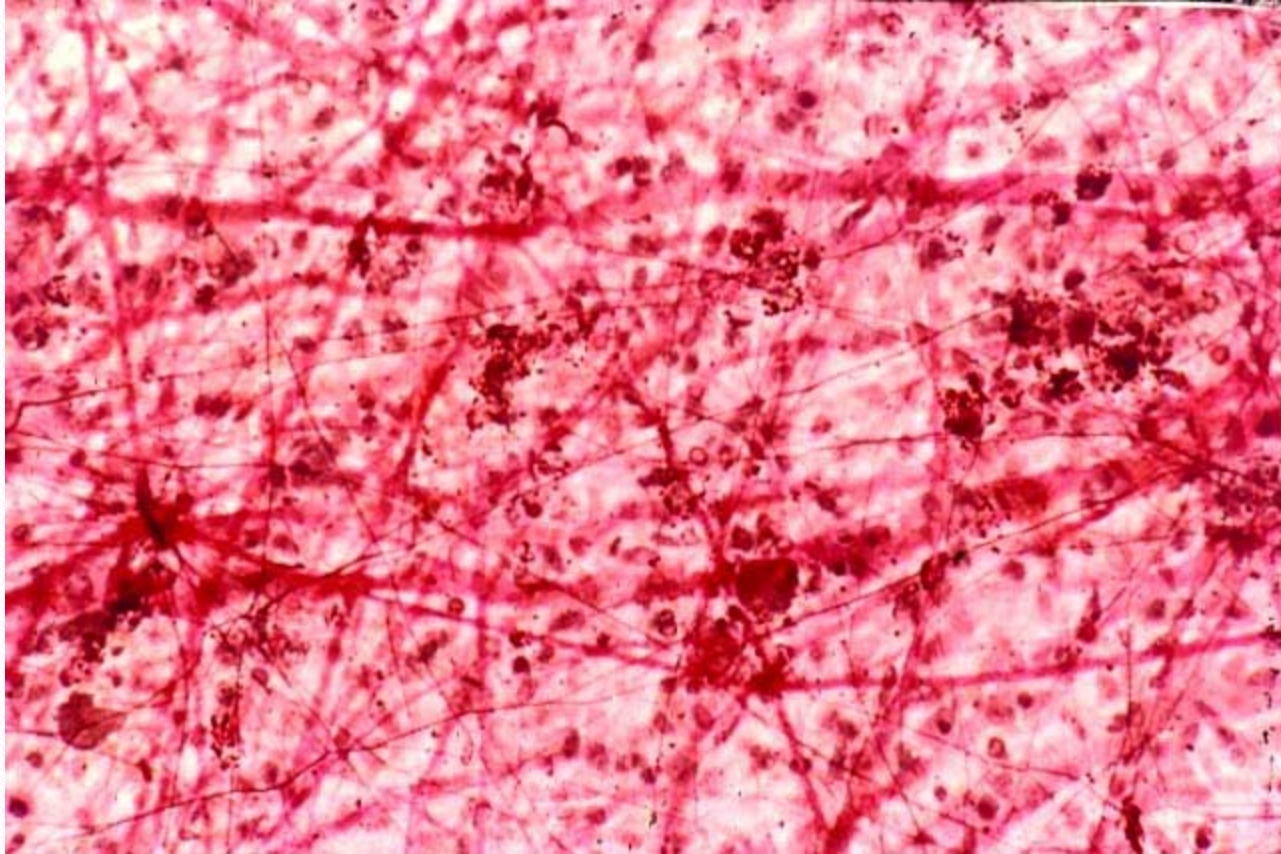
Identify the tissue type and its function.



Transitional Epithelium

- Stretches readily and permits distension by urine

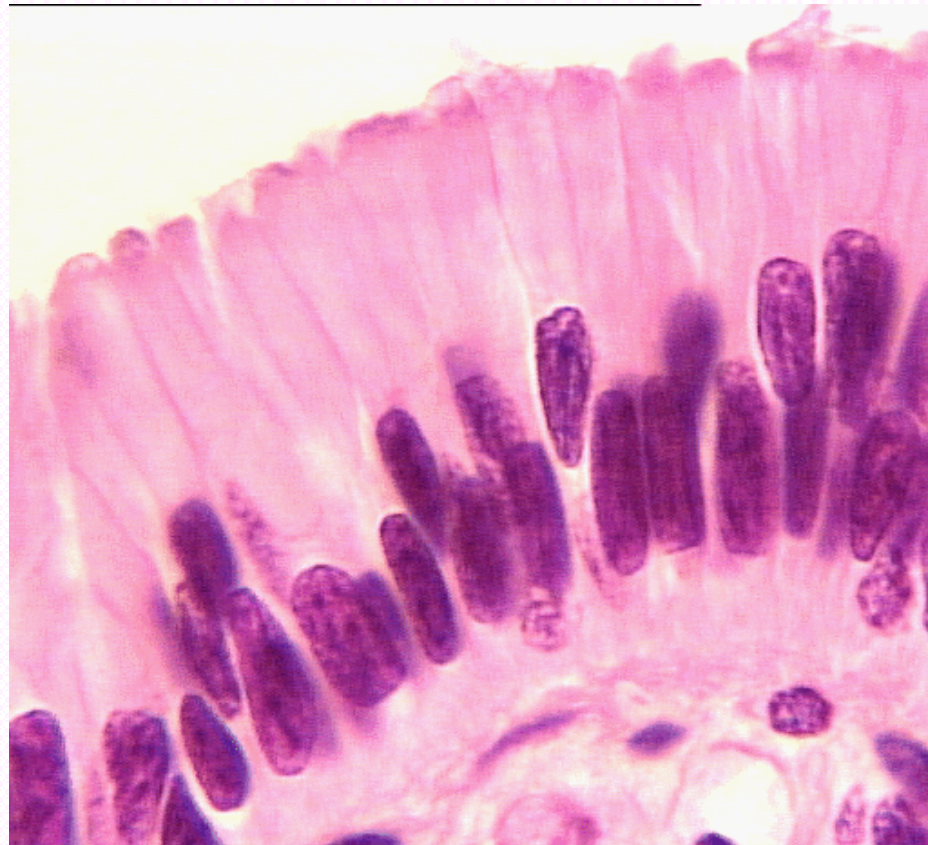
Identify the tissue type and its function.



Loose Areolar Connective Tissue

- Wraps and cushions organs

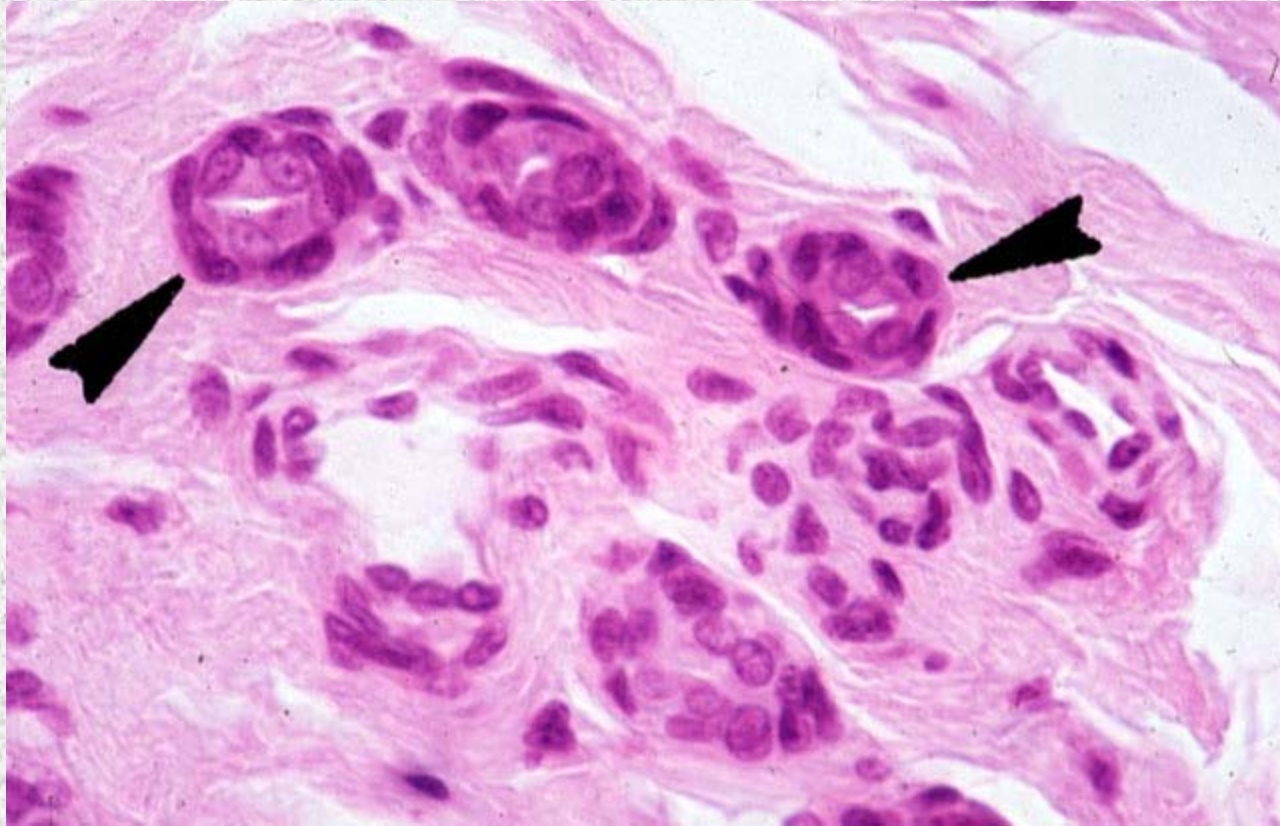
Identify the tissue type and its function.



Pseudostratified Columnar Epithelium

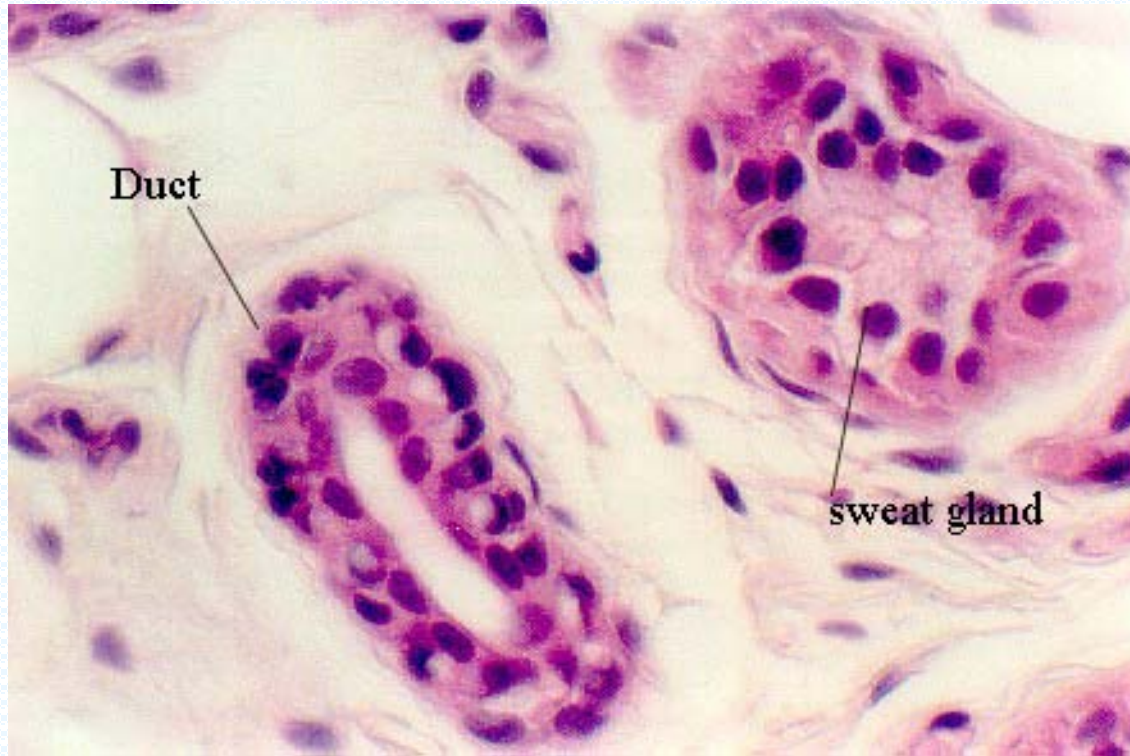
- Secretion of mucus

Identify the structure indicated.



Stratified Cuboidal Epithelium
Basement Membrane

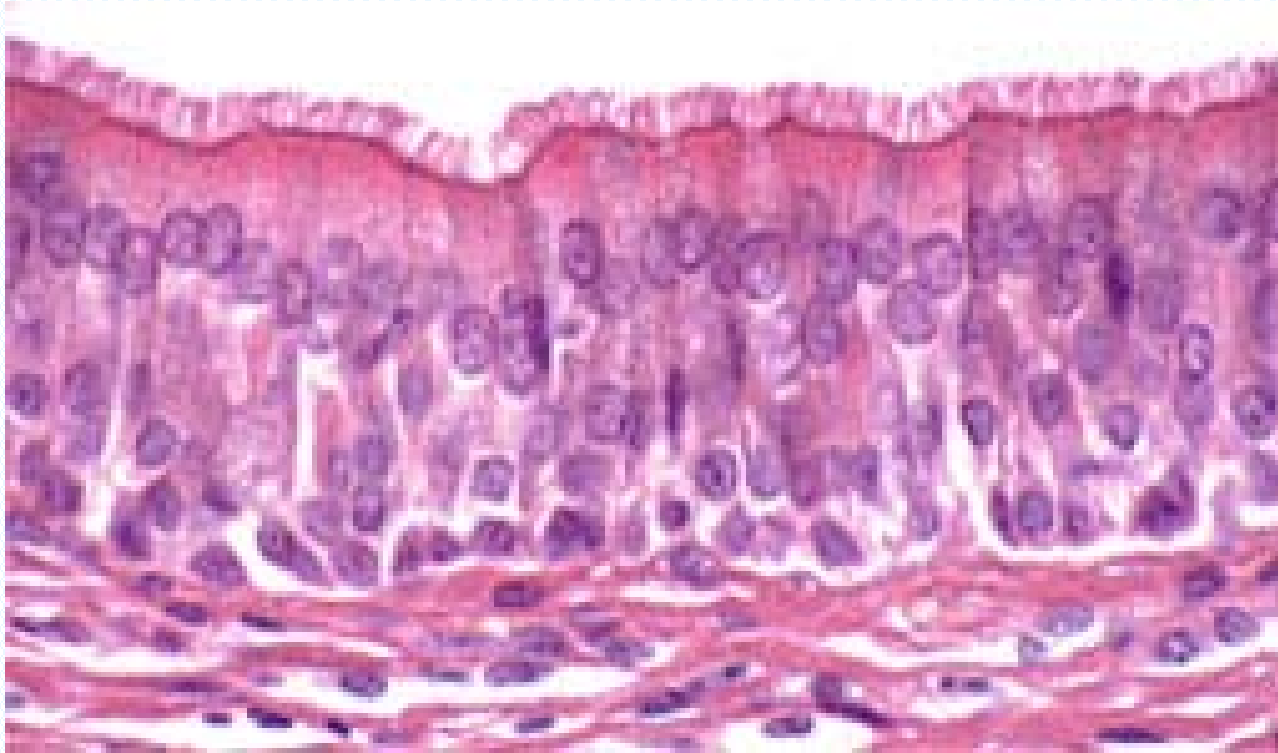Identify the tissue type and a location where it is found.



Stratified Cuboidal Epithelium

- Largest ducts of sweat, mammary and salivary glands

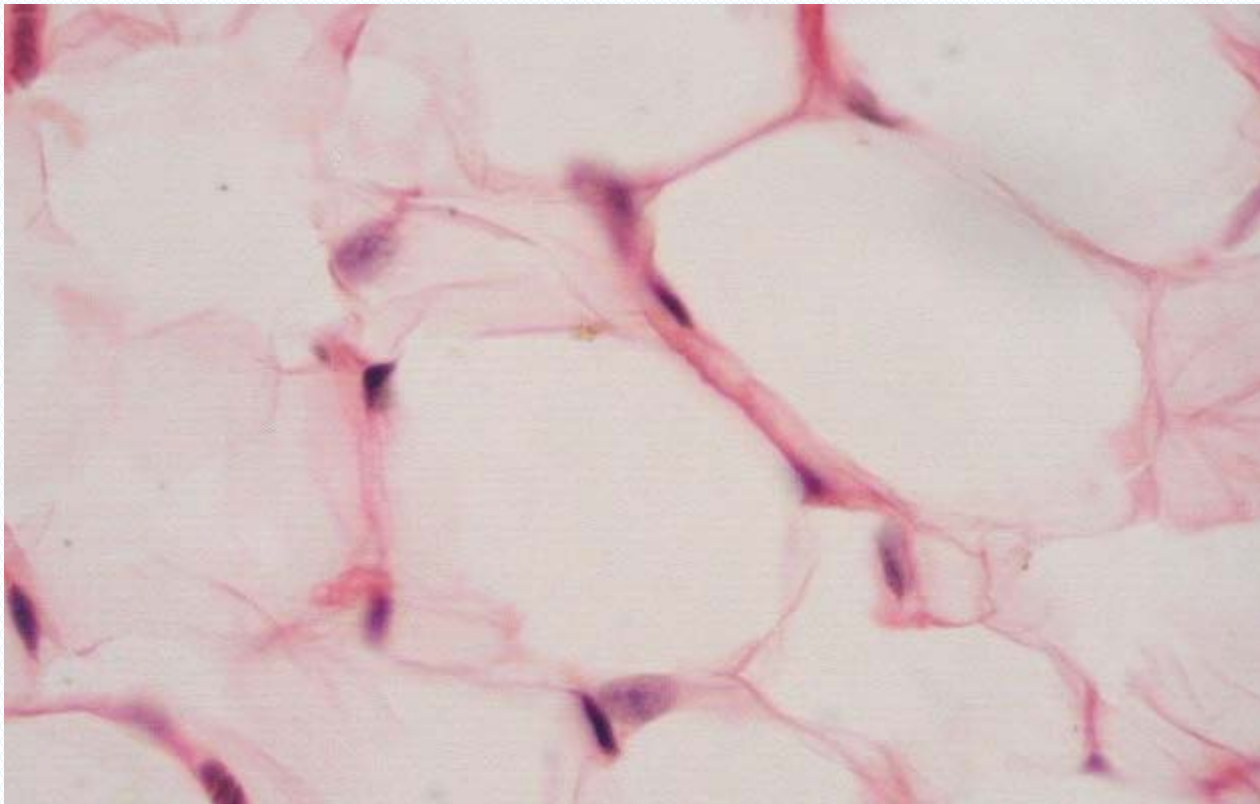
Identify the tissue type and a location where it is found.



Ciliated Pseudostratified Columnar Epithelium

- Trachea and most of the upper respiratory tract

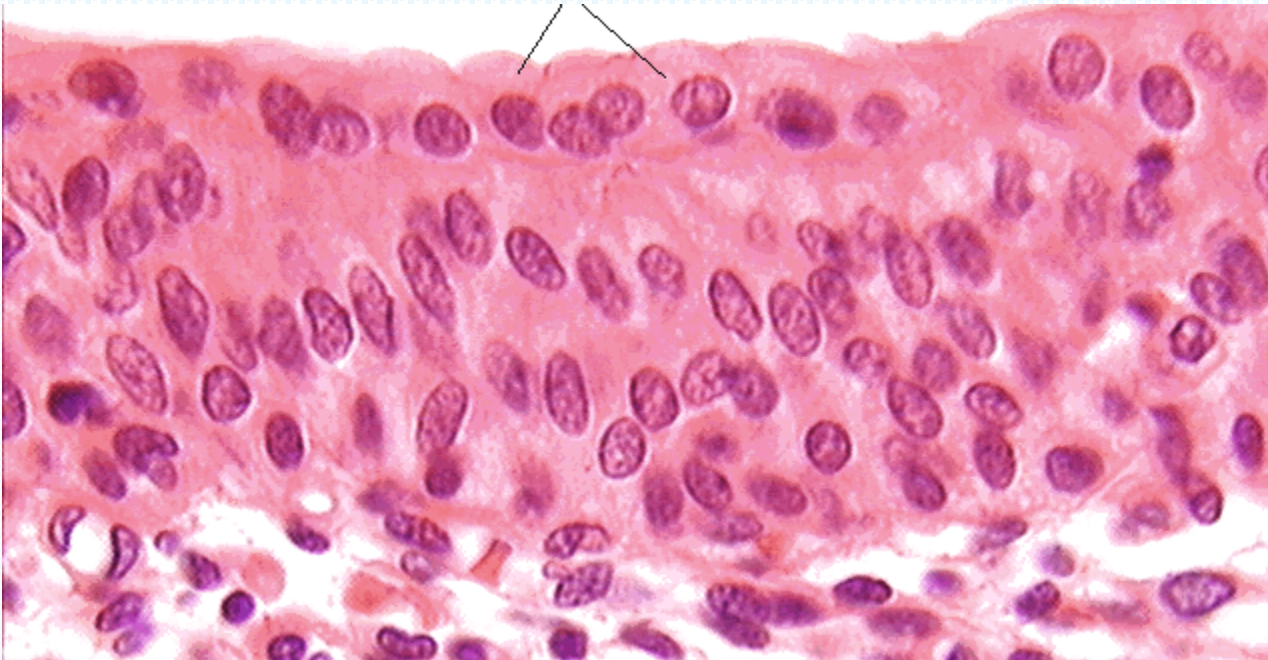
Identify the tissue type and a location where it is found.



Adipose Tissue

- Under skin
- Around kidneys
- Breasts
- Yellow bone marrow

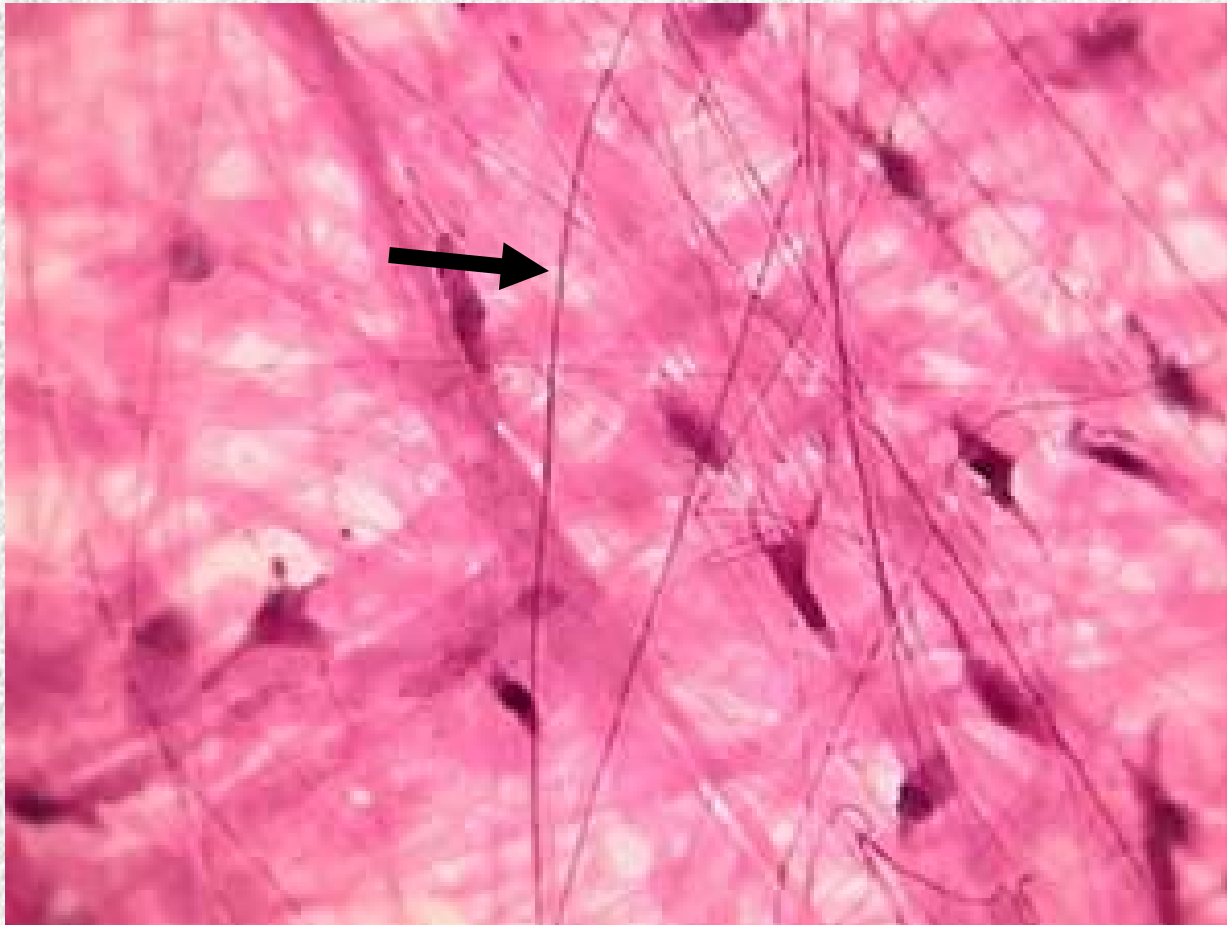
Identify the tissue type and a location where it is found.



Transitional Epithelium

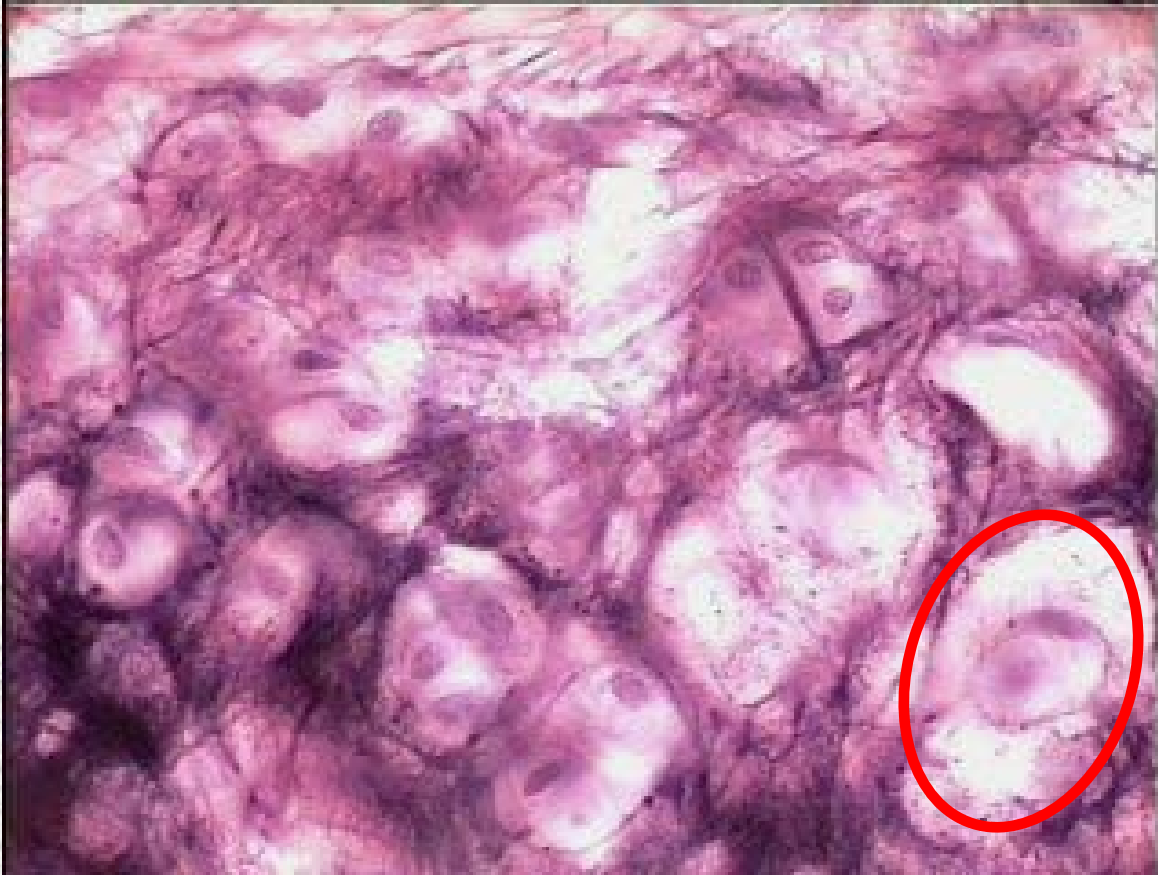
- Lines ureters, bladder and part of the urethra

Identify the structure indicated.



Loose Areolar Connective Tissue
Elastic Fiber

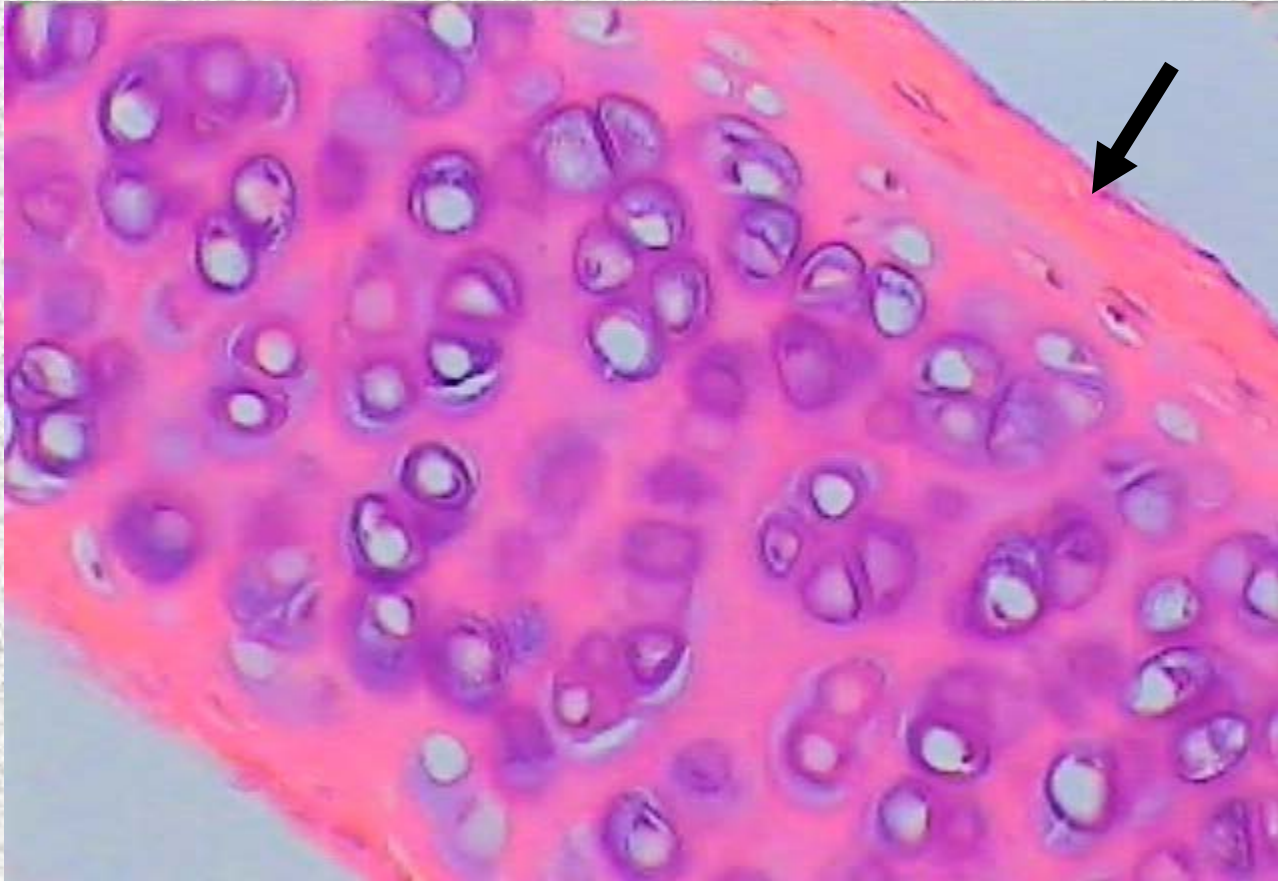
Identify the structure indicated.



Elastic Cartilage

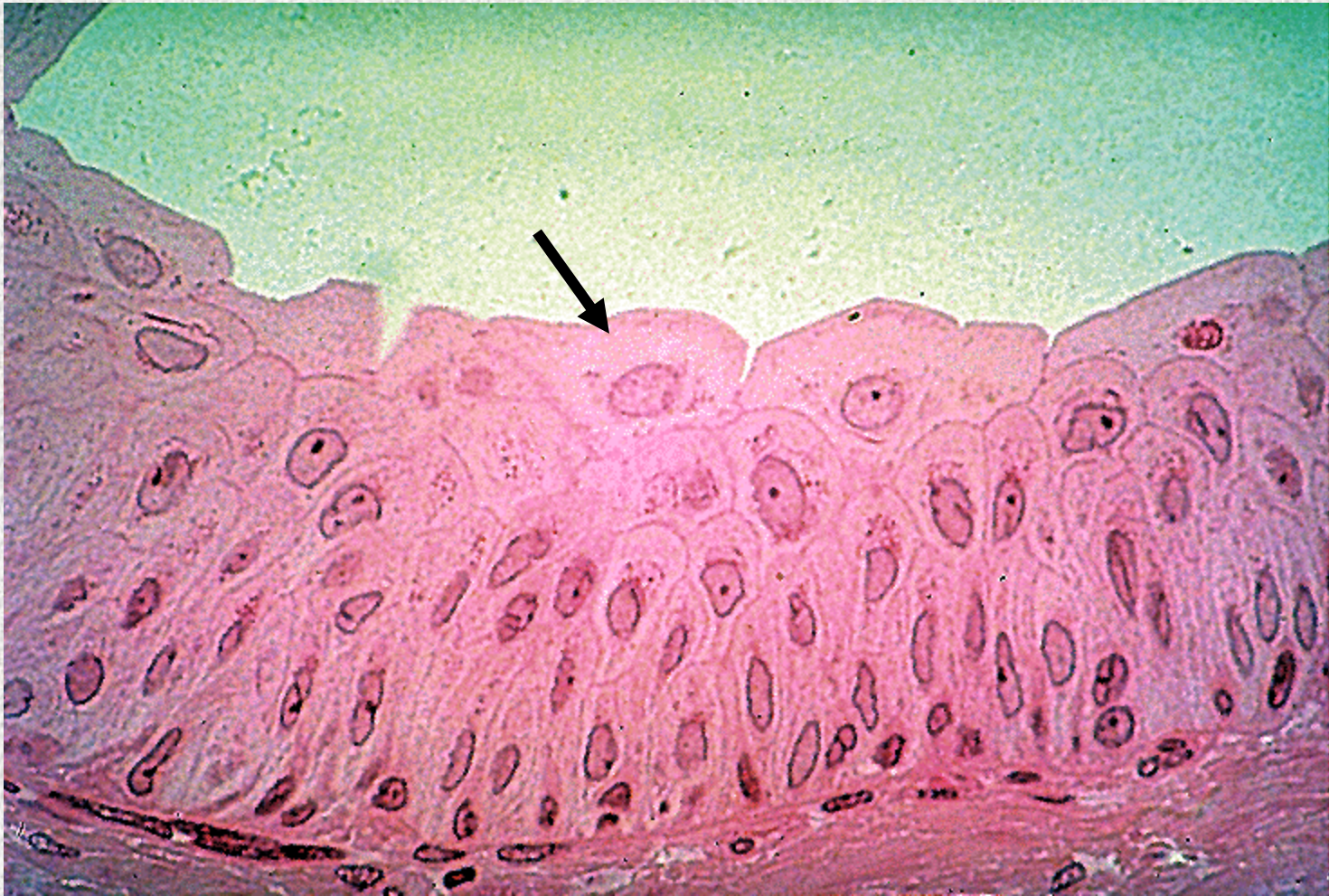Chondrocyte in lacuna

Identify the structure indicated.



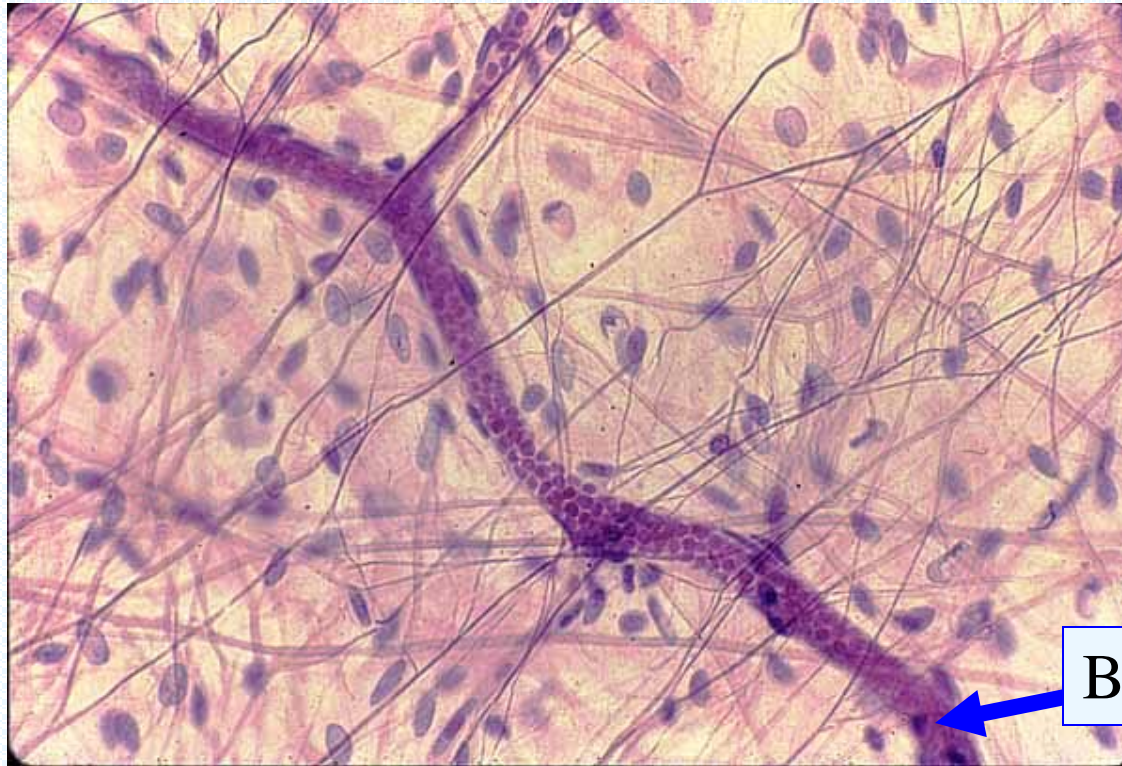Hyaline Cartilage
Perichondrium

Identify the structure indicated.



Transitional Epithelium
Dome shaped apical cells

Identify the tissue type and a location where it is found.

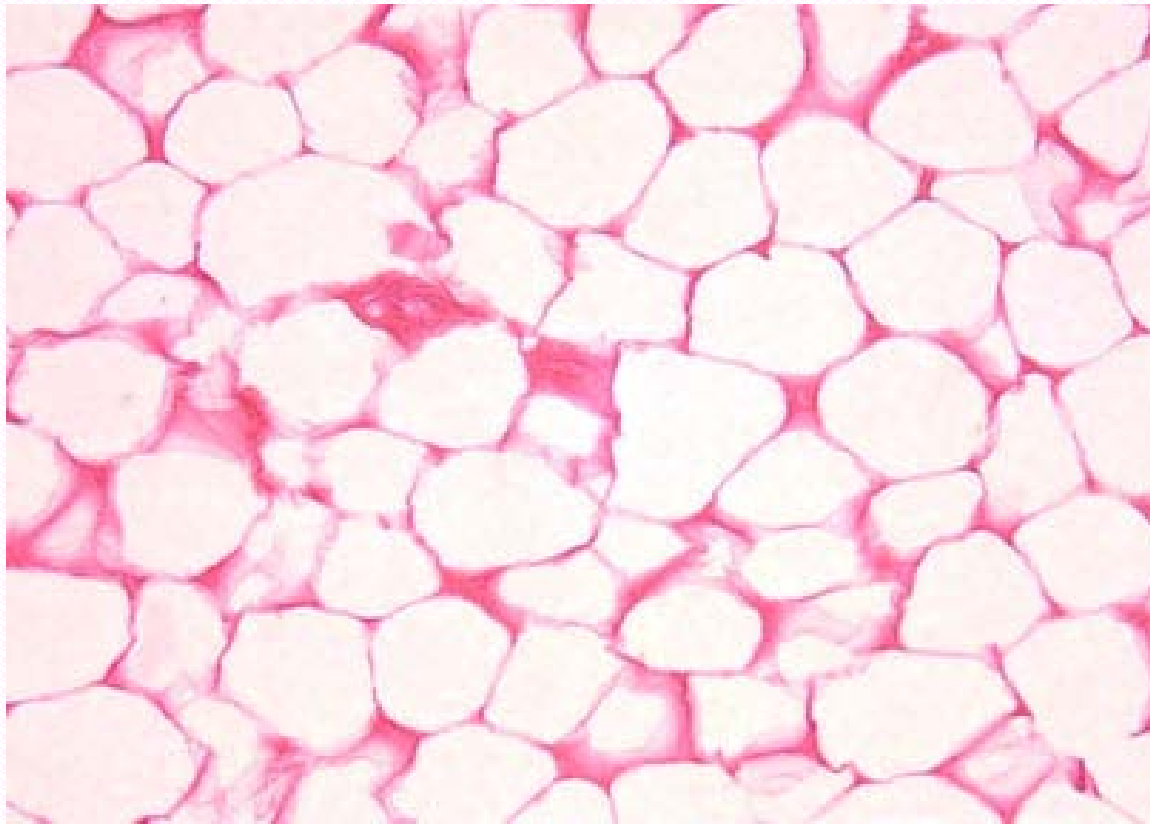


Blood Vessel

Loose Areolar Connective Tissue

- Papillary layer of dermis
- Hypodermis
- Around organs
- Basement membrane of mucous membranes
- Surrounding blood vessels

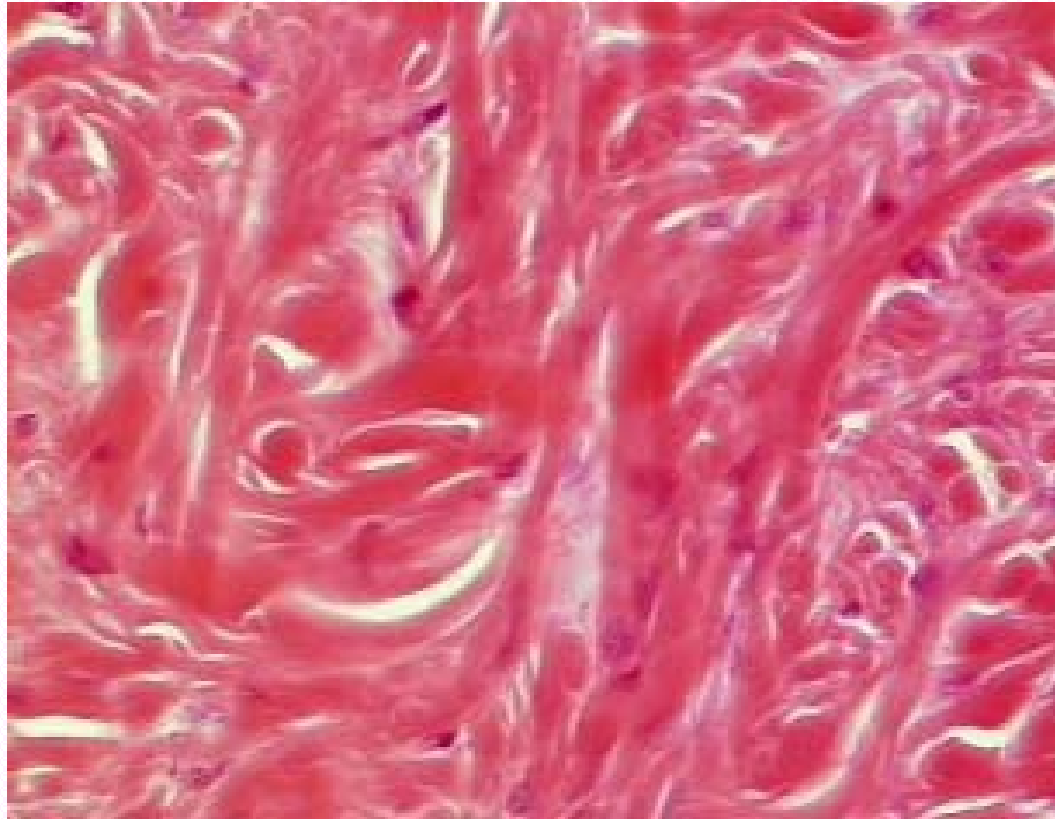
Identify the tissue type and its function.



Adipose Tissue

- Insulates against heat loss
- Reserve fuel source
- Supports and protects organs

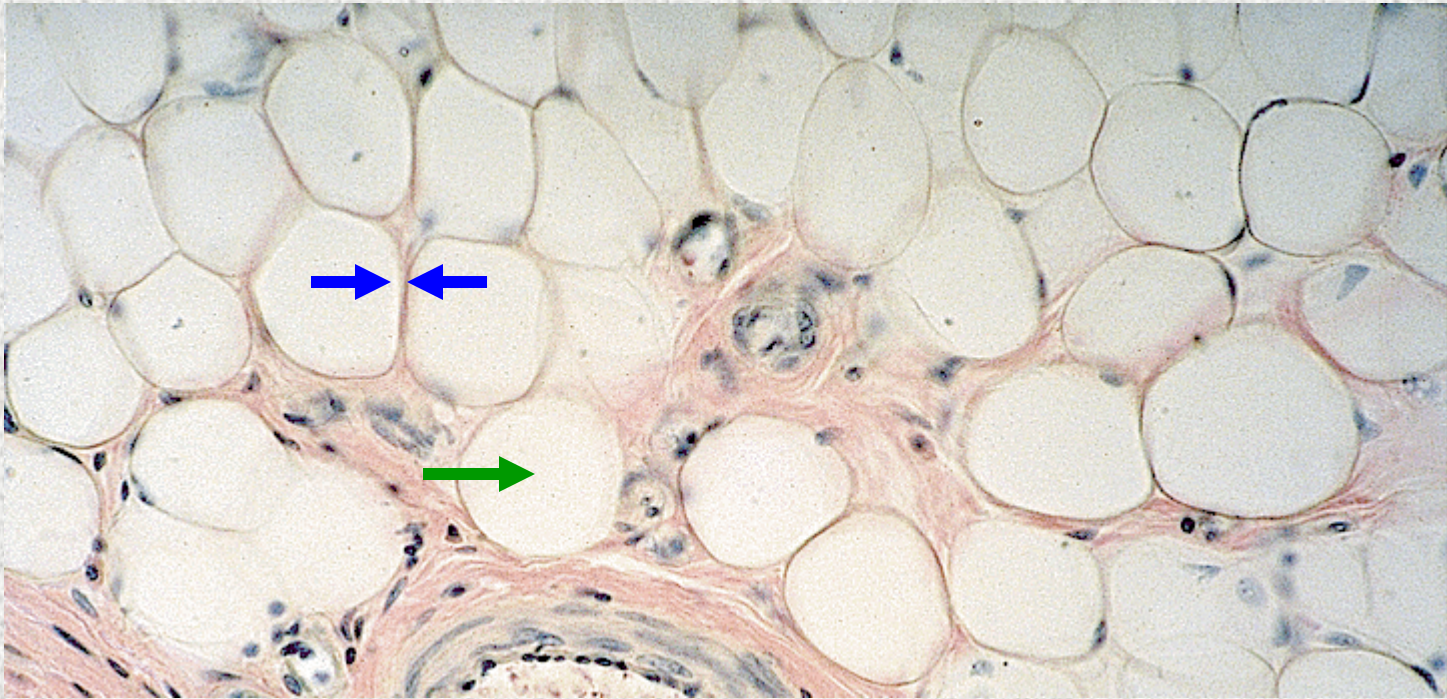
Identify the tissue type and its function.



Dense Irregular Connective Tissue

- Provides structural strength in areas where tension is exerted in many directions

Identify the structure indicated.

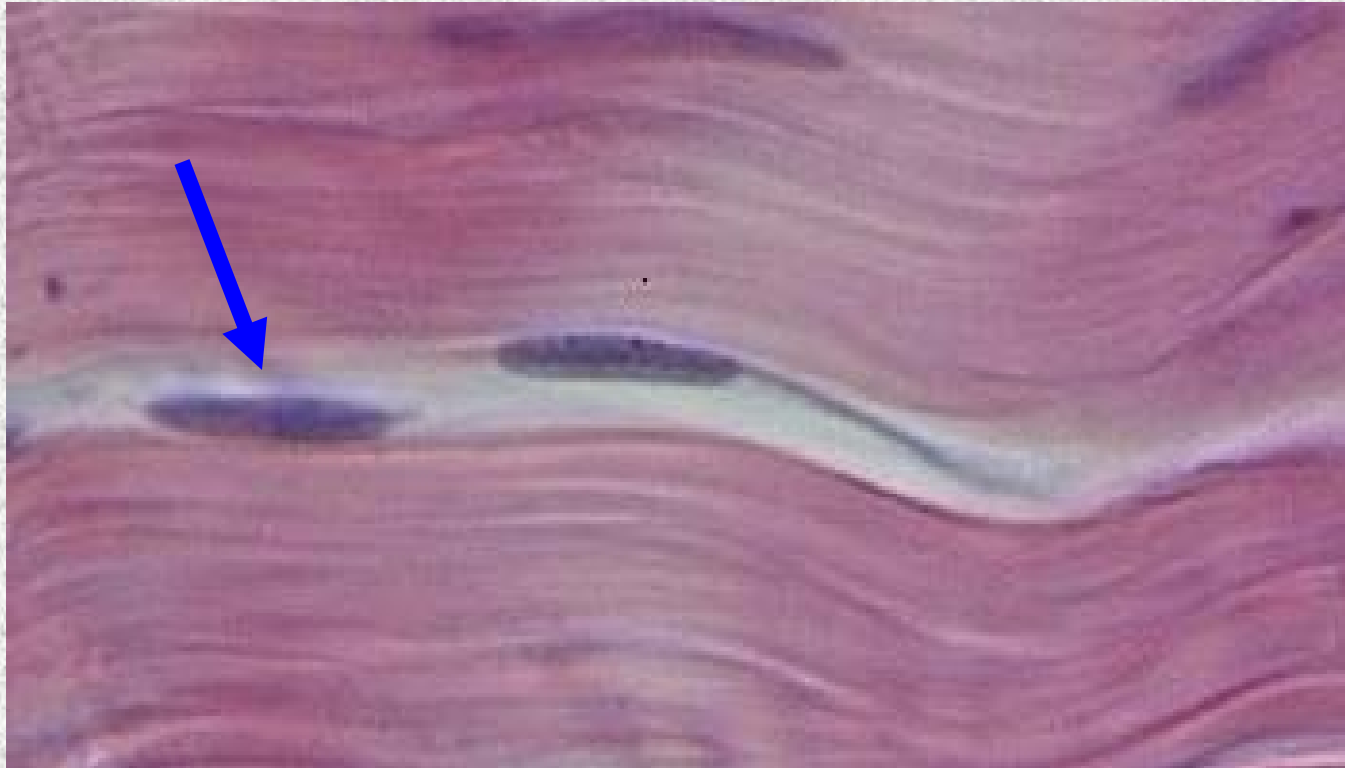

Adipose Tissue

Plasma Membrane

Vacuole containing fat droplet

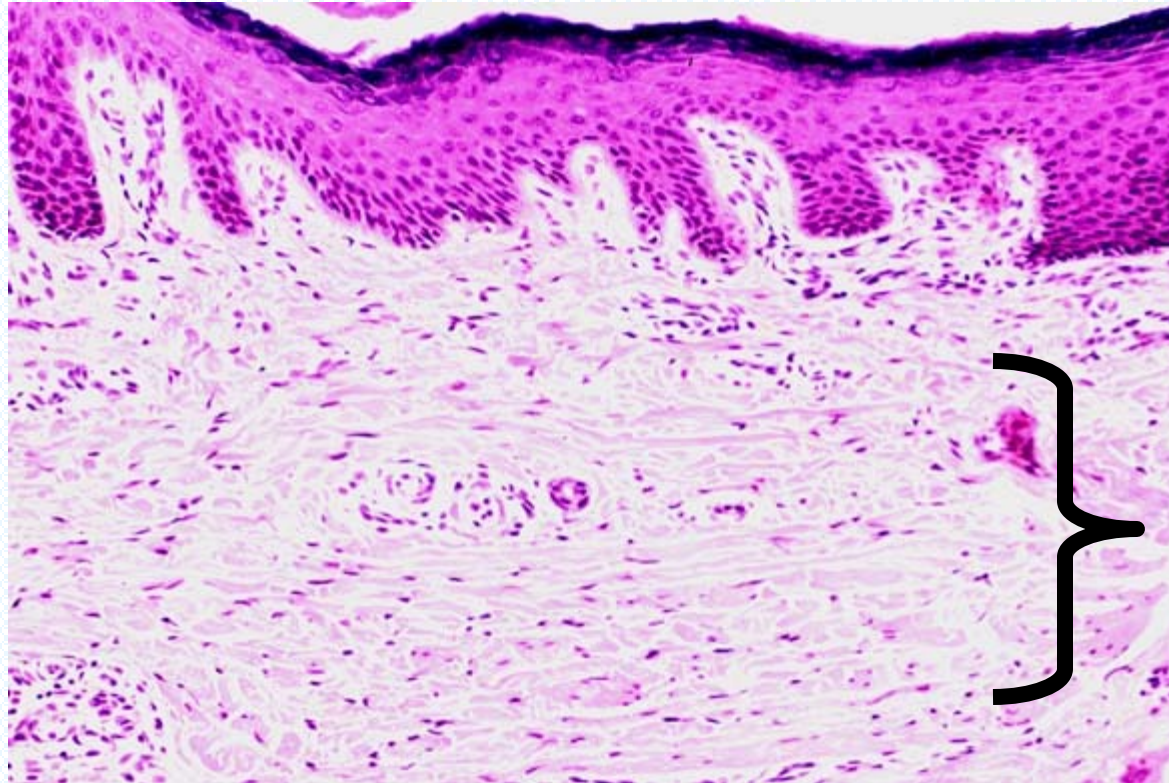
Identify the structure indicated.



**Dense Regular Connective
Tissue**

Fibroblast (nucleus)

Identify the tissue type and a location where it is found.

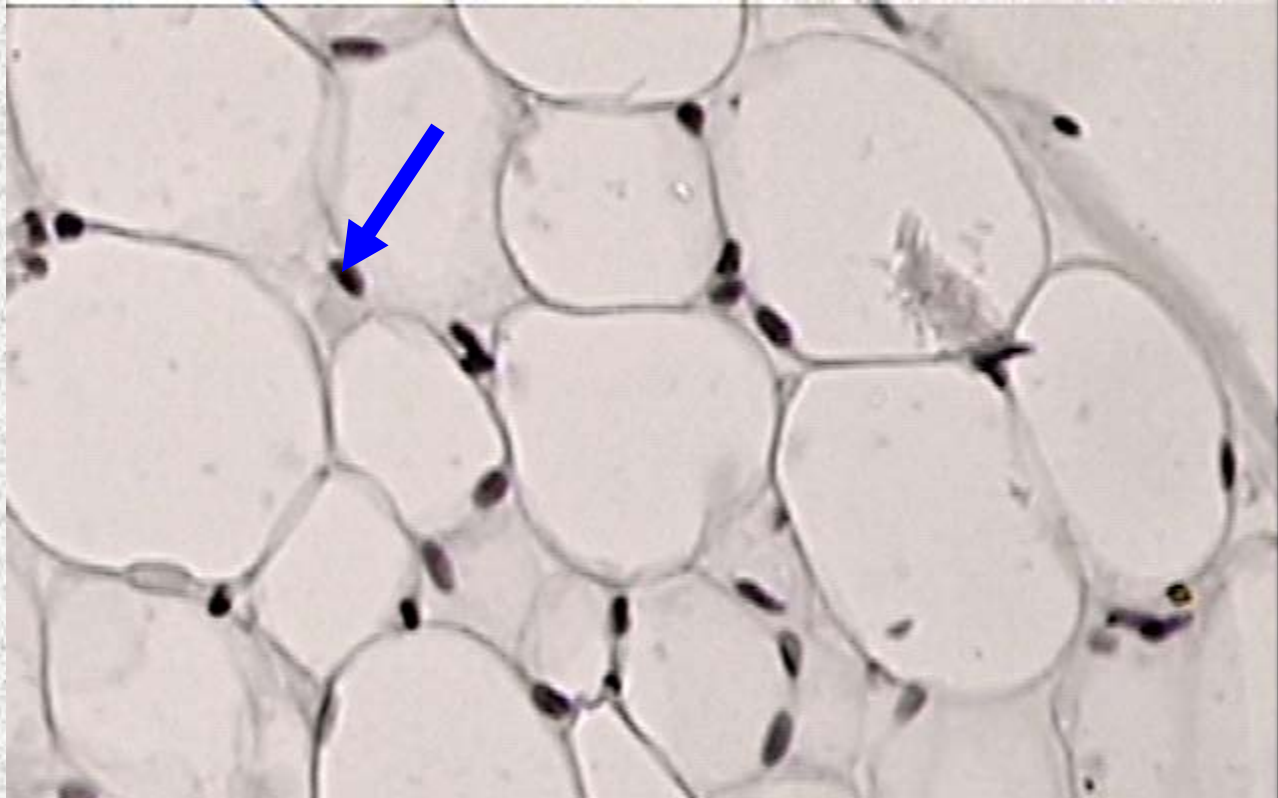


Dense Irregular Connective

- Reticular layer of dermis
- Submucosa of digestive tract
- Fibrous capsules of organs and joints

Tissue

Identify the structure indicated.



Adipose Tissue

Nucleus of adipocyte

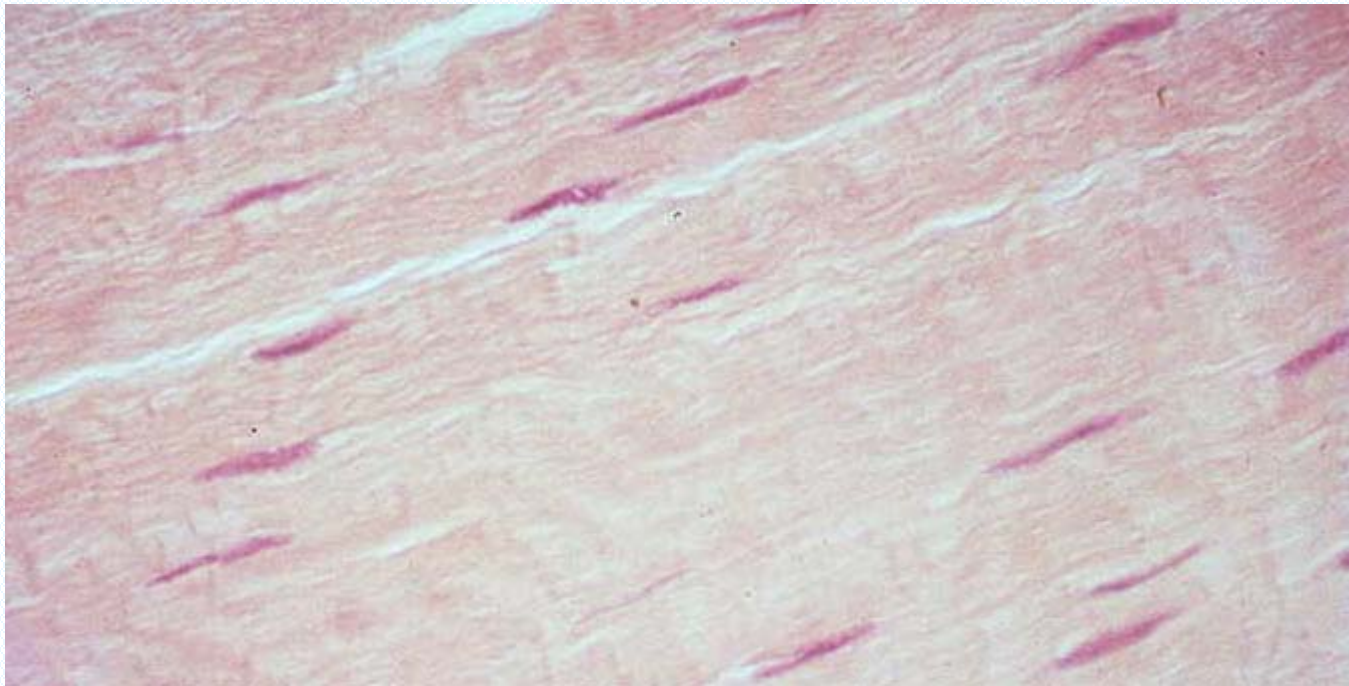
Identify the structure indicated.



Dense Regular Connective Tissue

Bundle of collagen fibers running parallel to each other.

Identify the tissue type and a location where it is found.



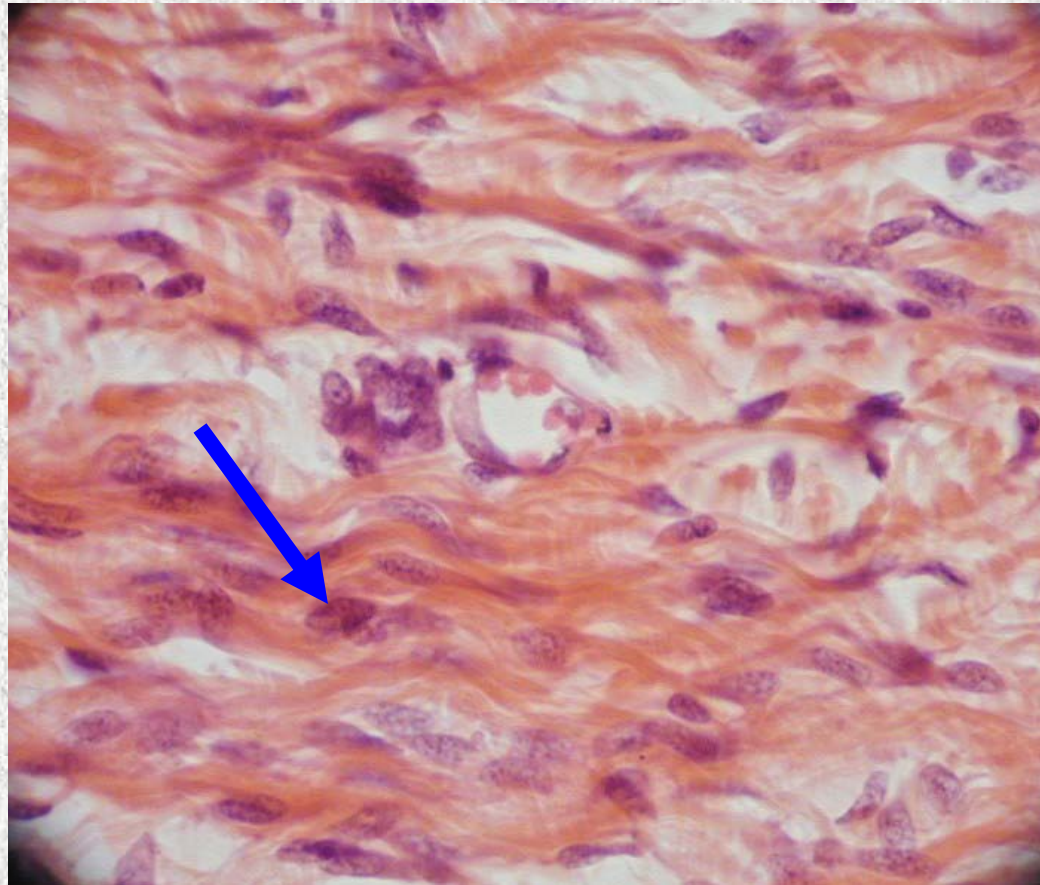
Dense Regular Connective Tissue

- Tendons

- Ligaments

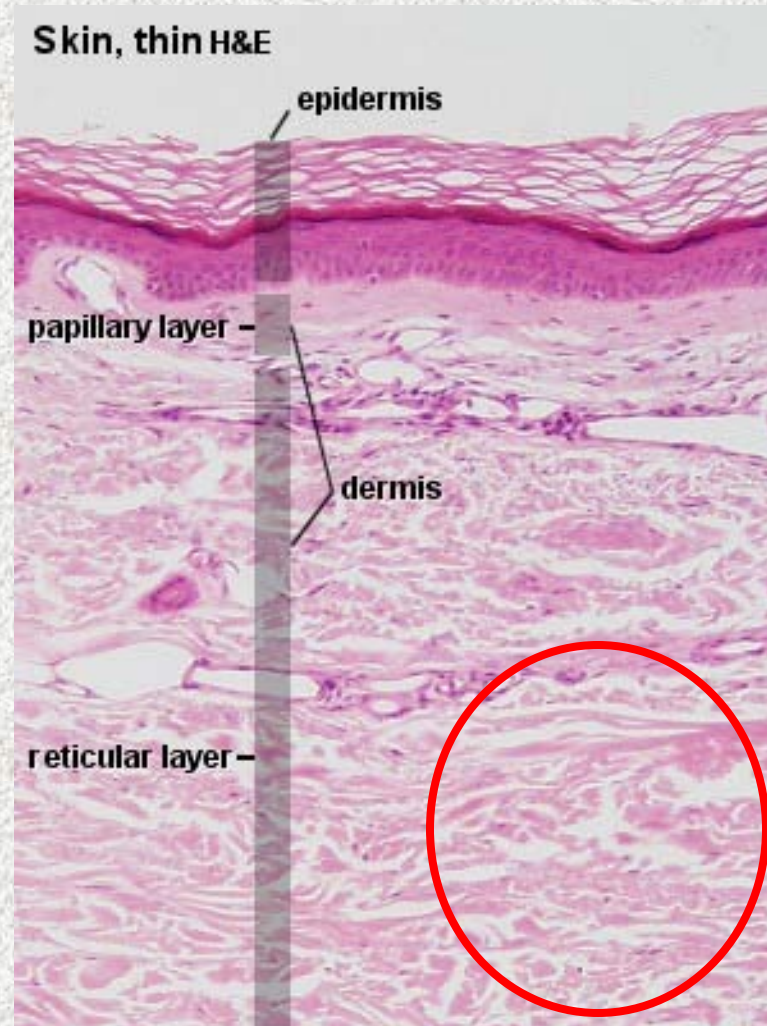
- Aponeuroses

Identify the structure indicated.



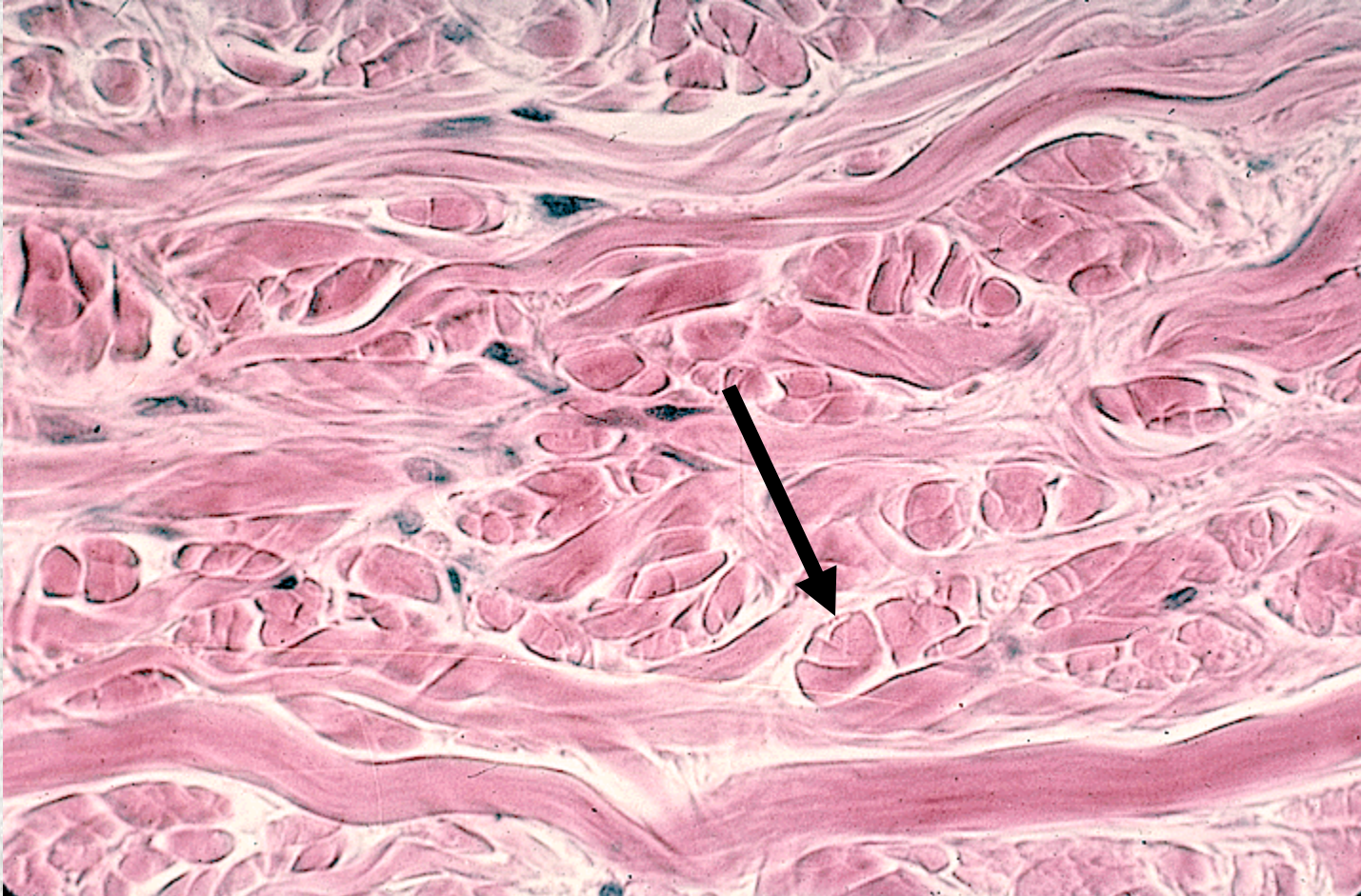
**Dense Irregular Connective
Tissue**

Identify the tissue type indicated.



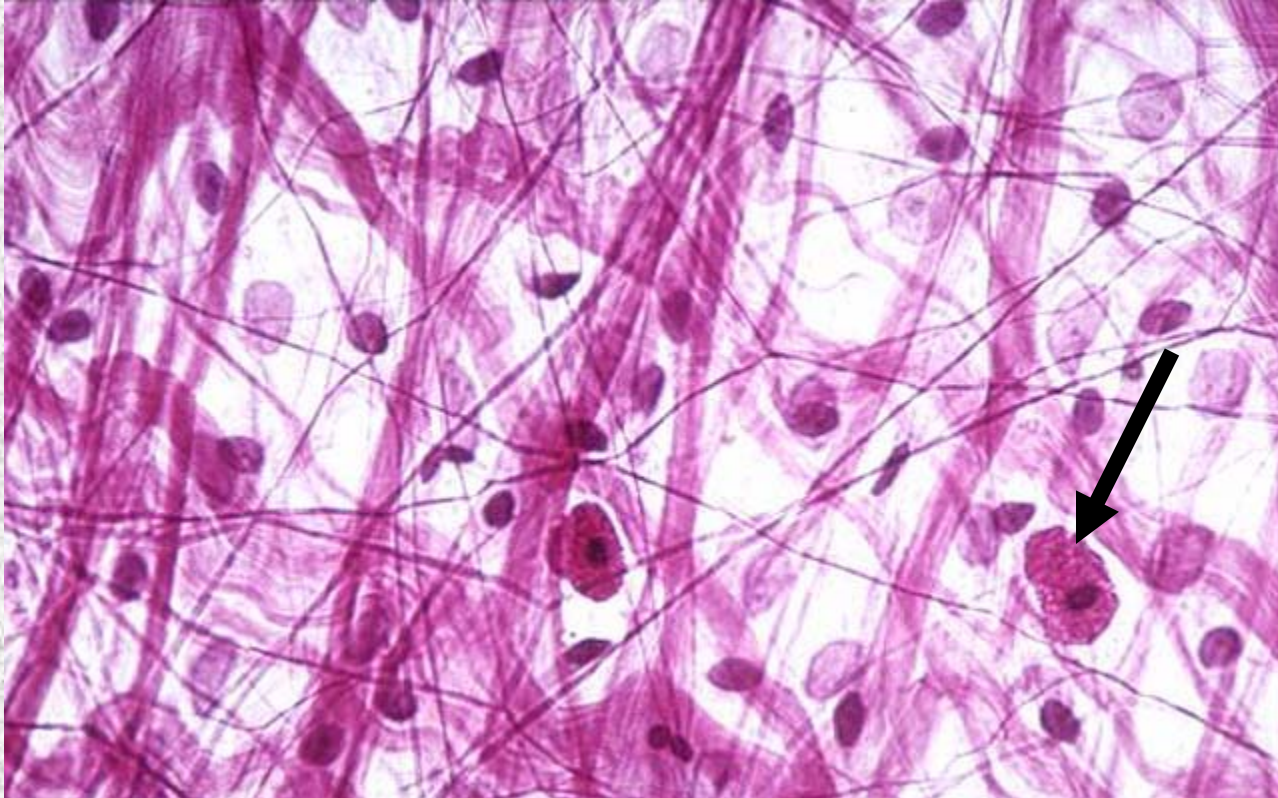
Dense Irregular Connective Tissue

Identify the structure indicated.



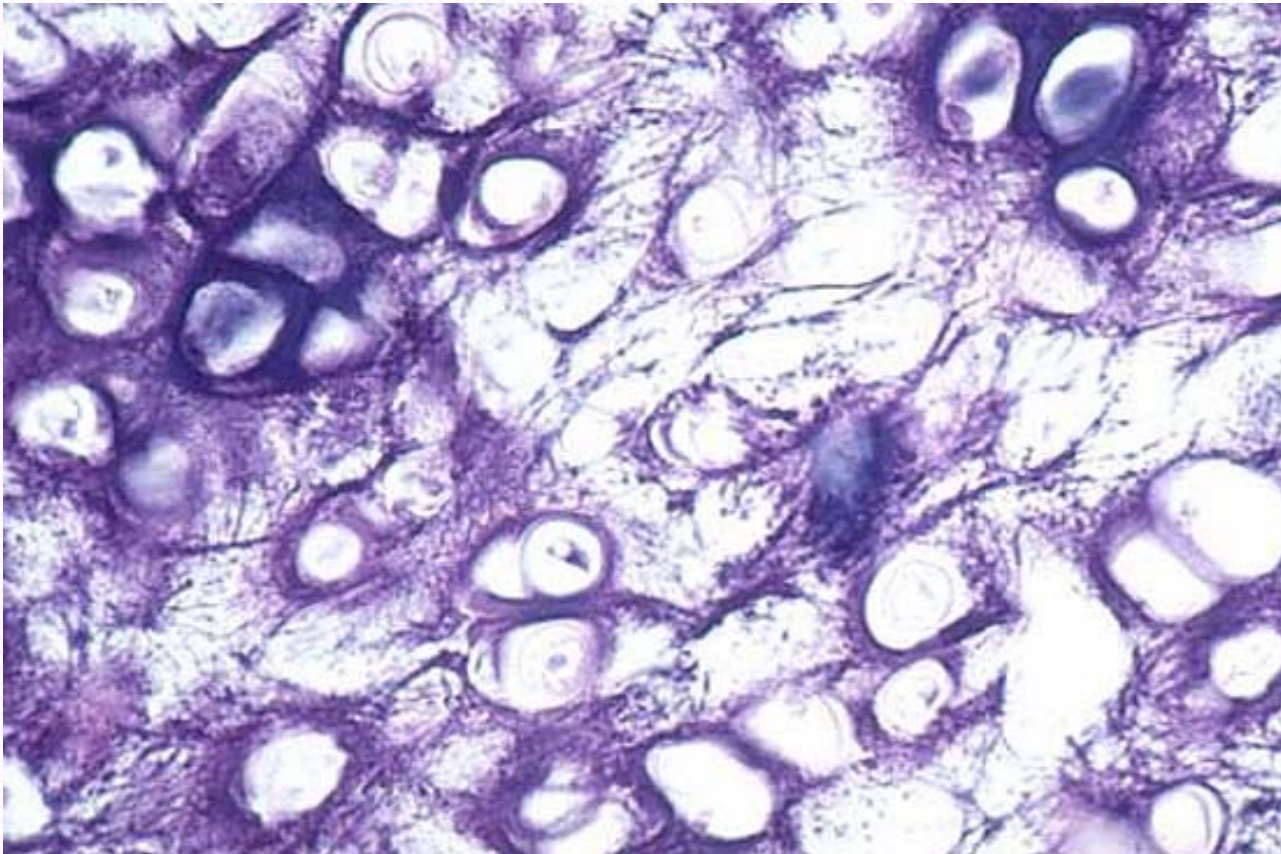
Dense Irregular Connective Tissue
Bundle of collagen fibers

Identify the structure indicated.



Loose Areolar Connective Tissue
Macrophage

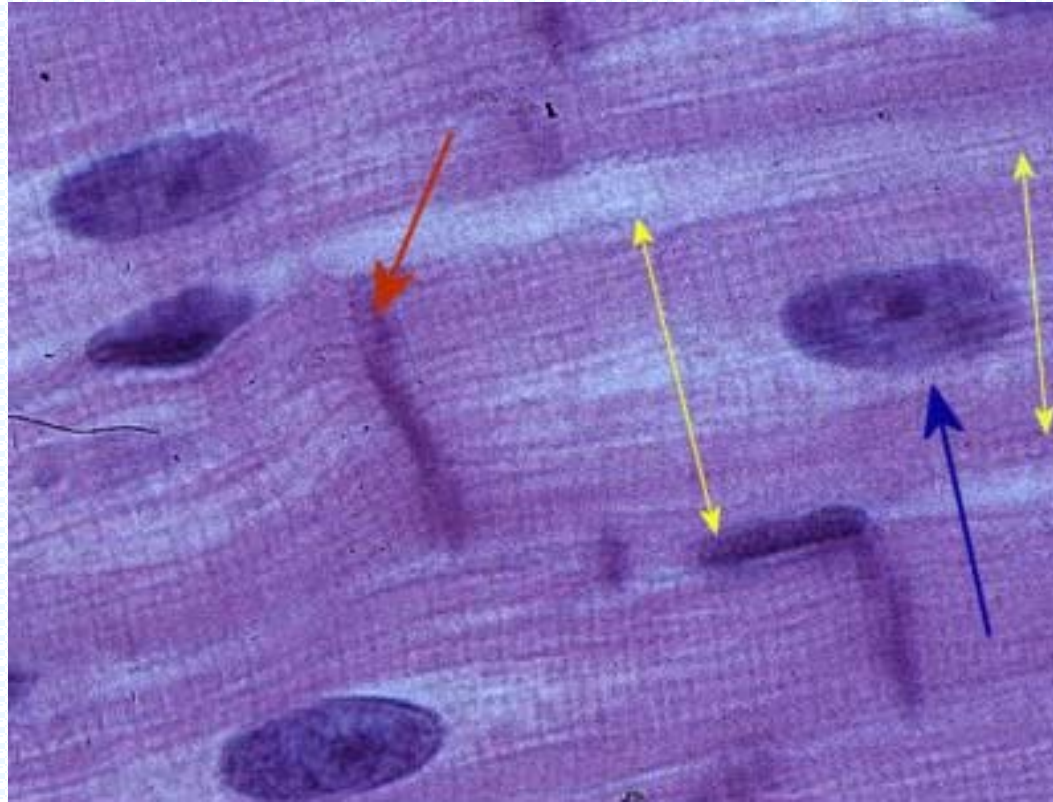
Identify the tissue type and its function.



Elastic Cartilage

- Maintains structure while allowing great flexibility

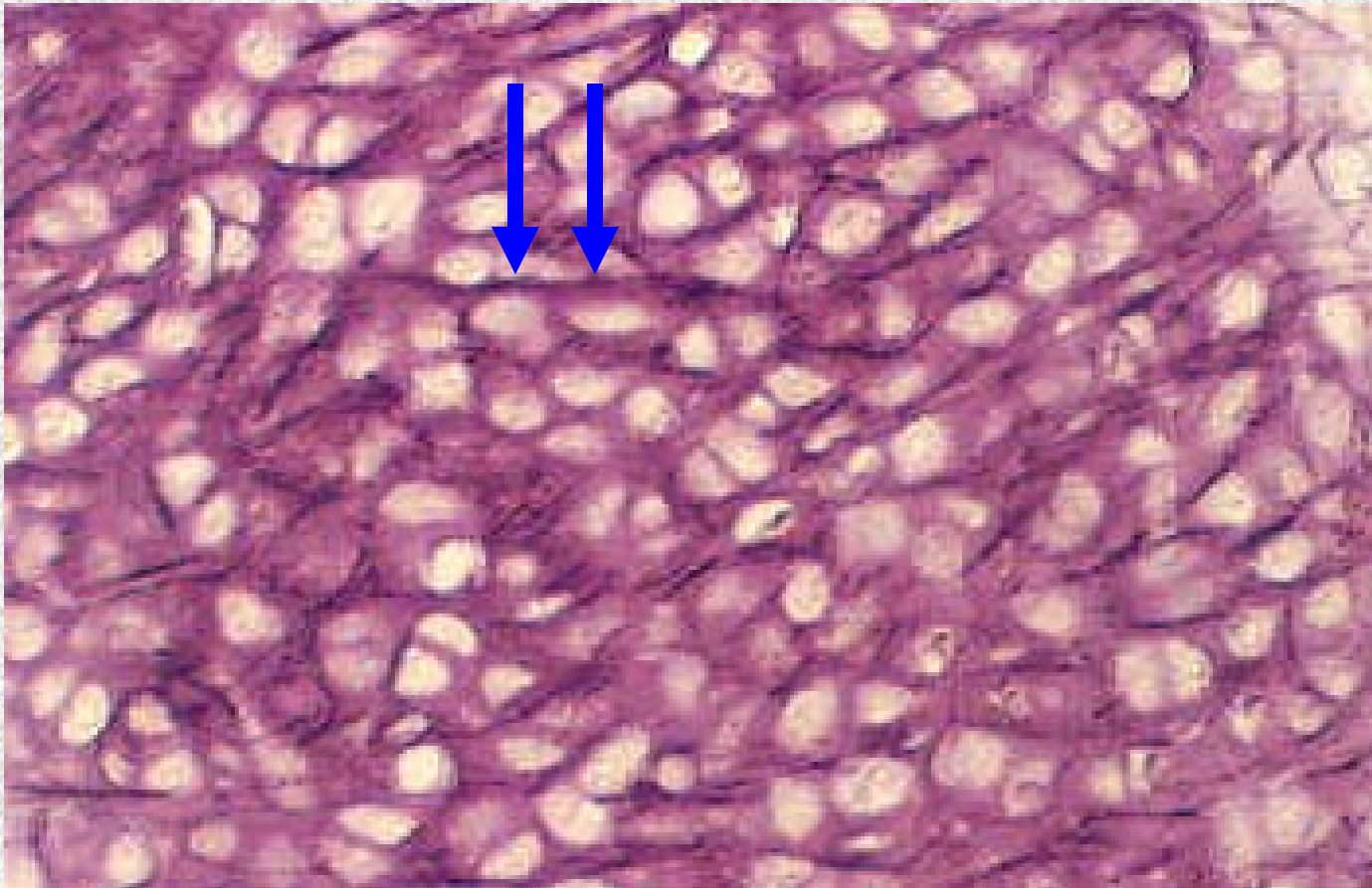
Identify the tissue type and a location where it is found.



Cardiac Muscle

•Heart

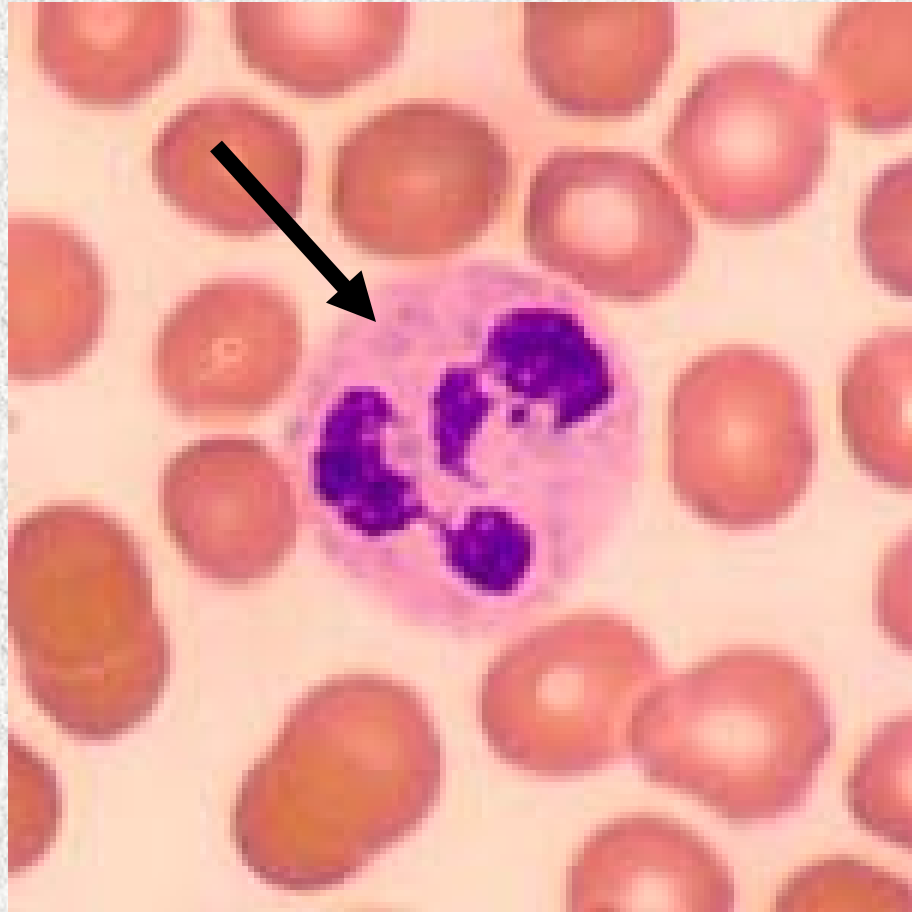Identify the structure indicated.



Elastic Cartilage

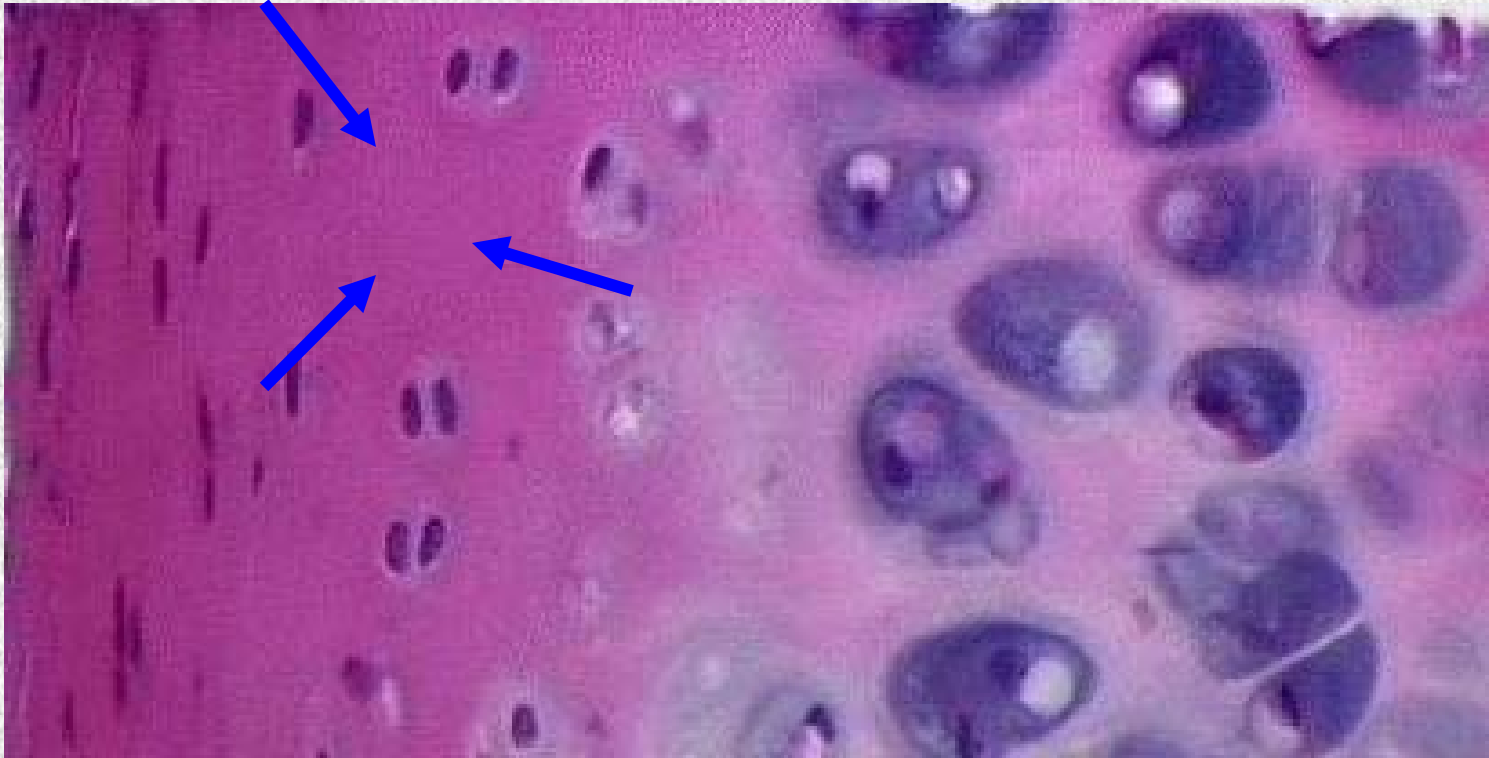Elastic Fibers

Identify the structure indicated.



White Blood Cell

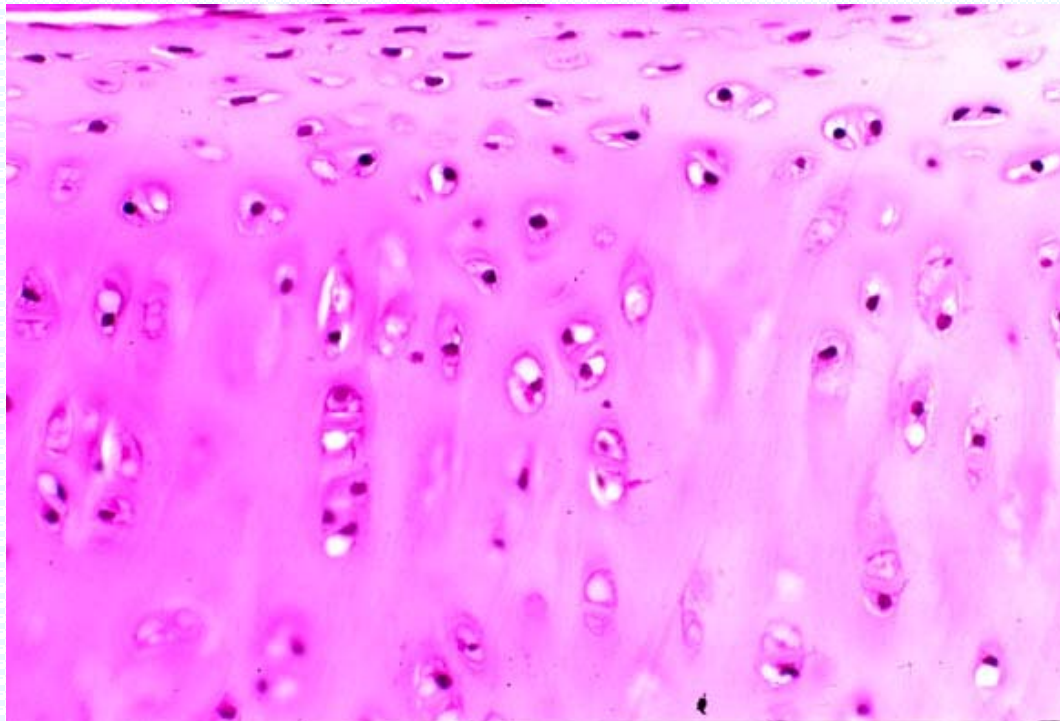
Identify the structure indicated.



Hyaline Cartilage

Matrix: notice the smooth glassy appearance (elastic cartilage has a

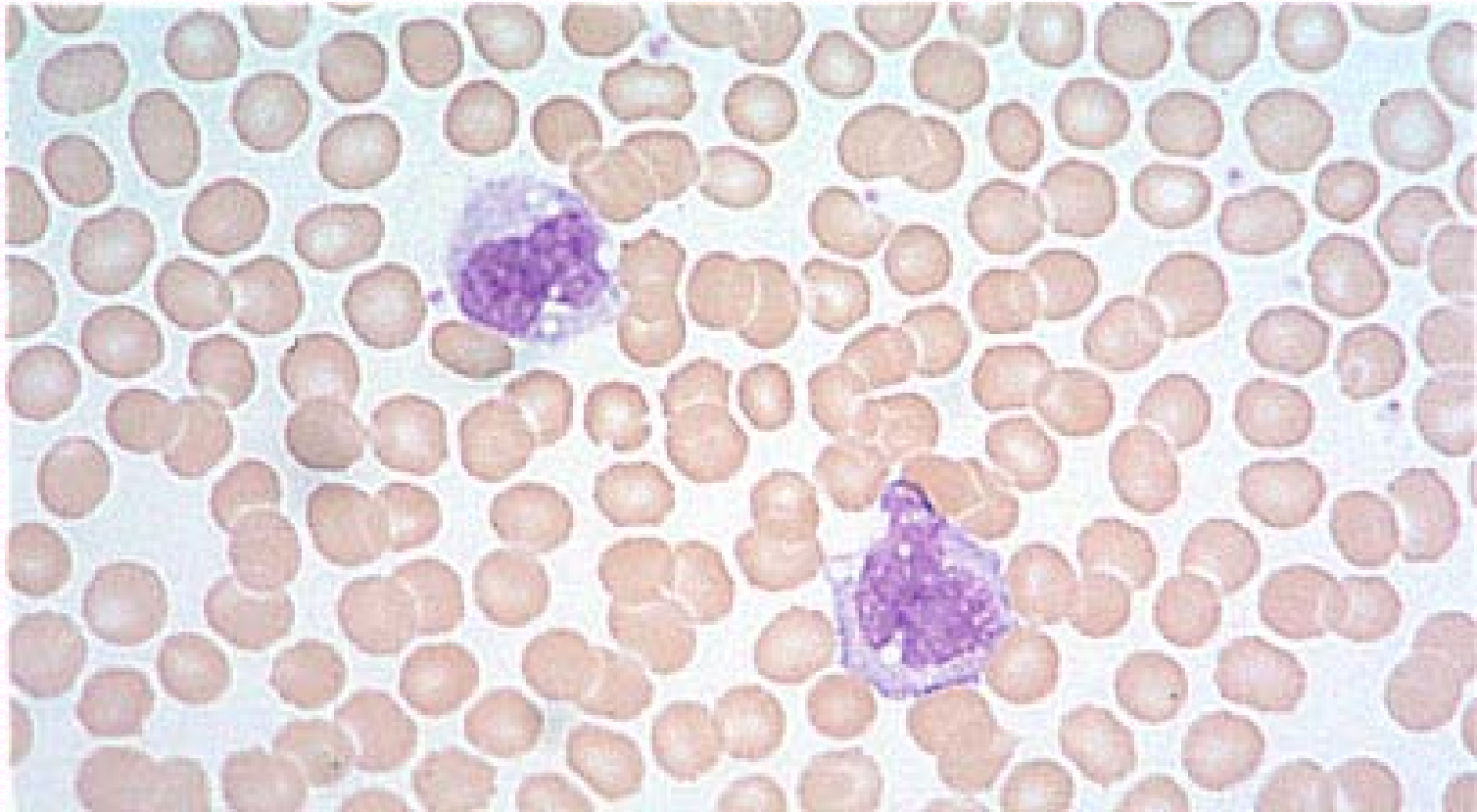
Identify the tissue type and a location where it is found.



Hyaline Cartilage

- Embryonic skeleton
- articular surface of long bones
- nose
- costal cartilages
- trachea

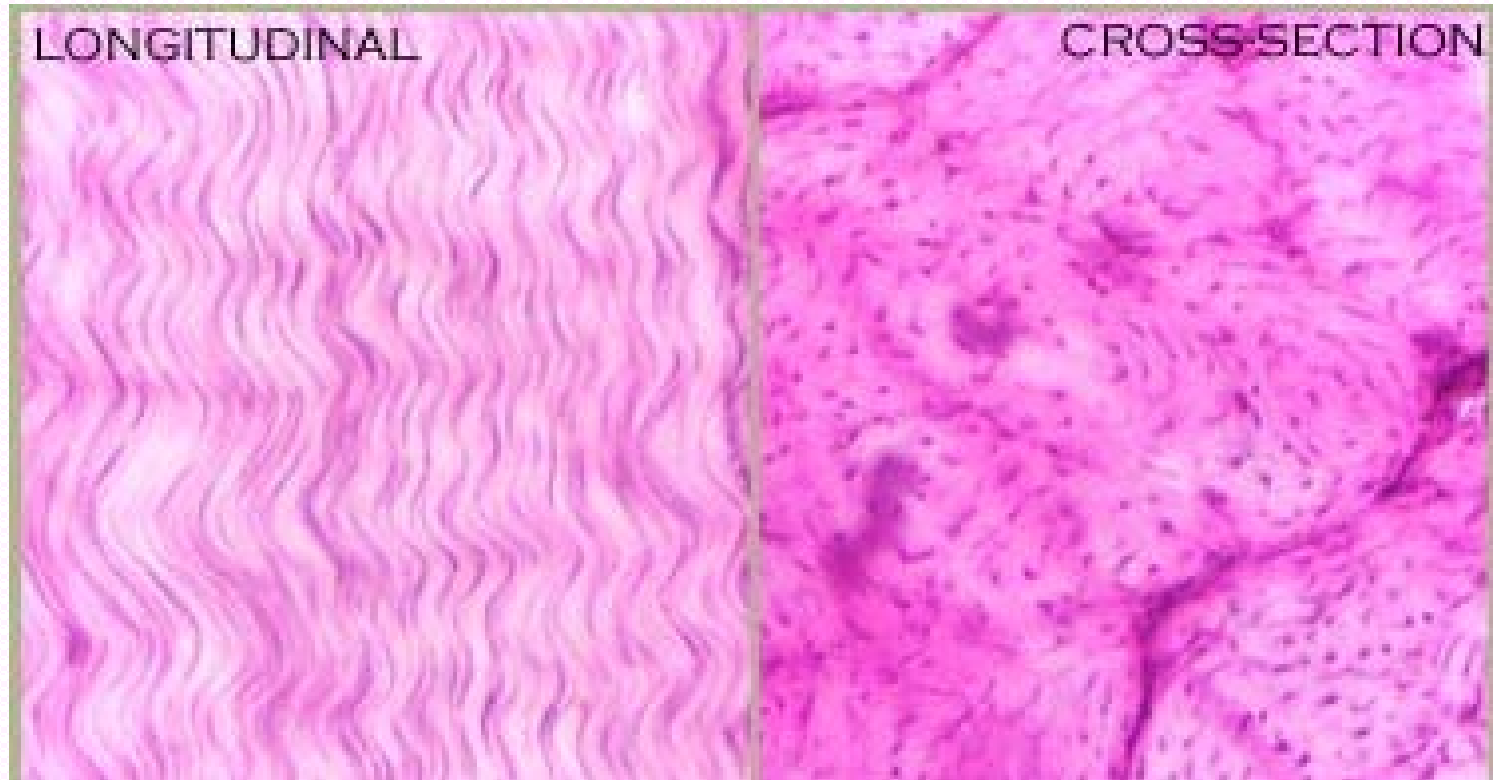
Identify the tissue type and its function.



Blood

- Transports respiratory gases, nutrients, wastes and other substances

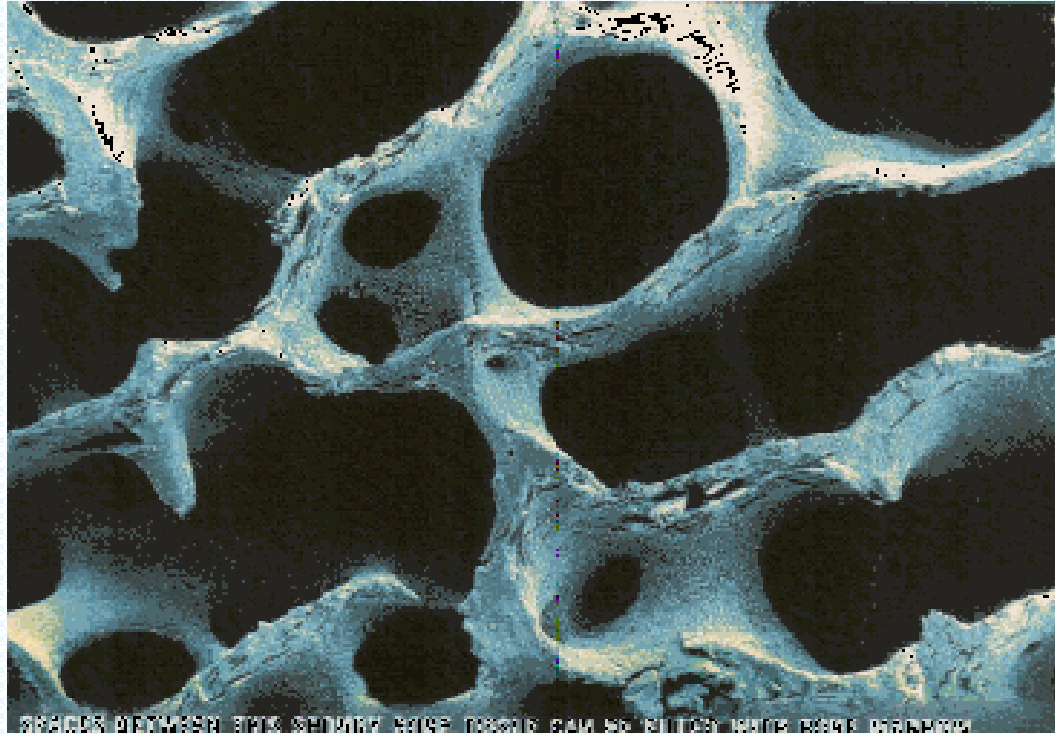
Identify the tissue type and its function.



Dense Regular Connective Tissue

- Provides strong attachment between structures that have forces pulling in one direction

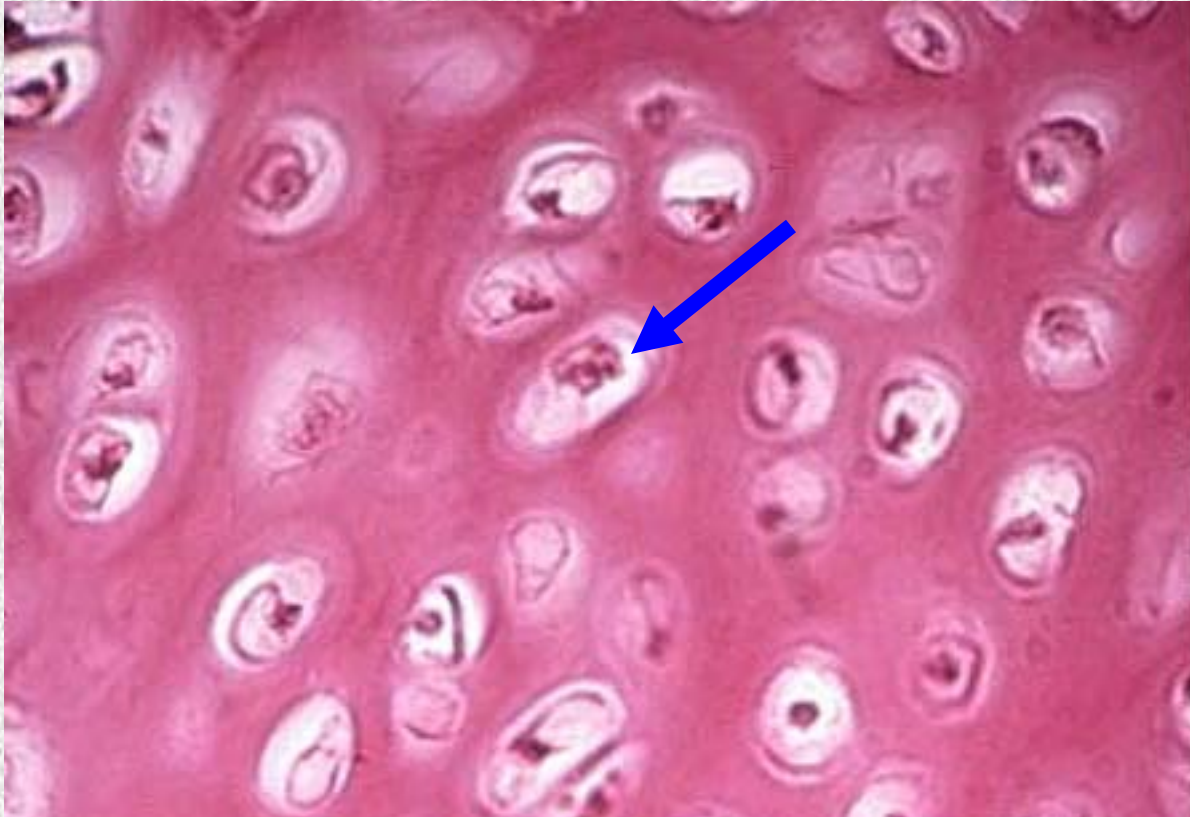Identify the tissue type and a location where it is found.



Spongy Bone Tissue

- Epiphysis of Long bones
- Dipole of Flat bones

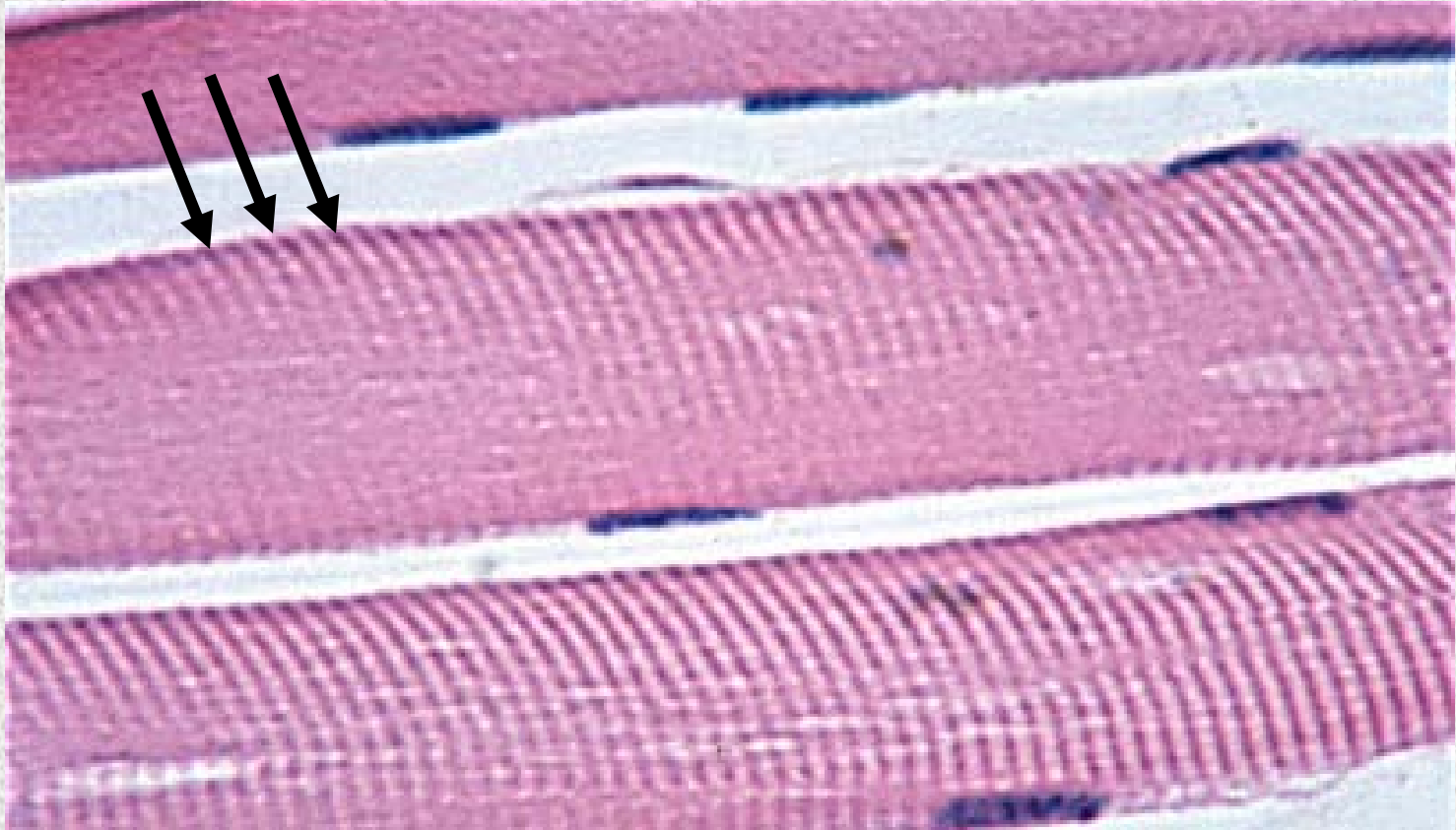
Identify the structure indicated.



Hyaline Cartilage

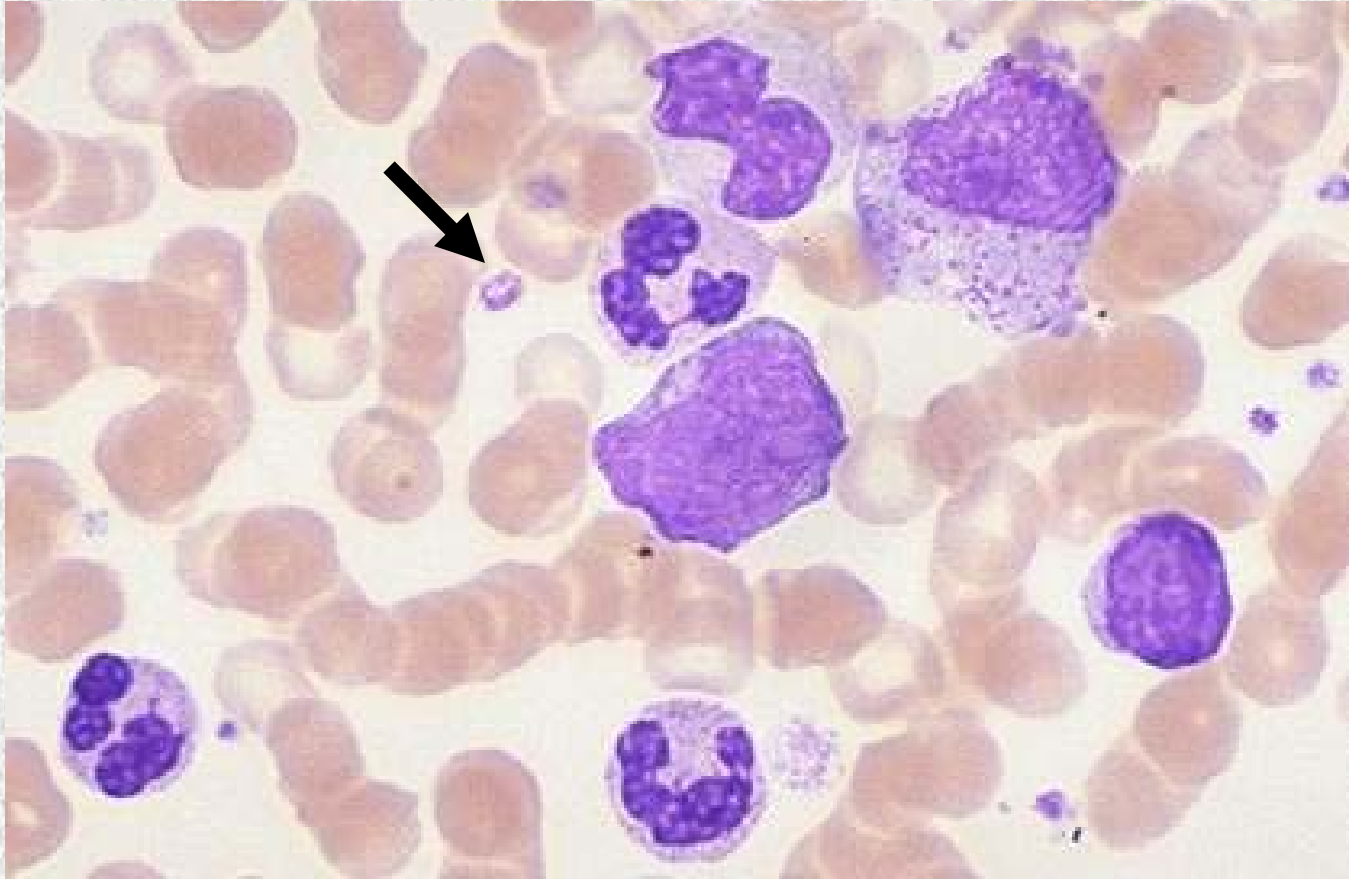
Chondrocyte in lacuna

Identify the structure indicated.



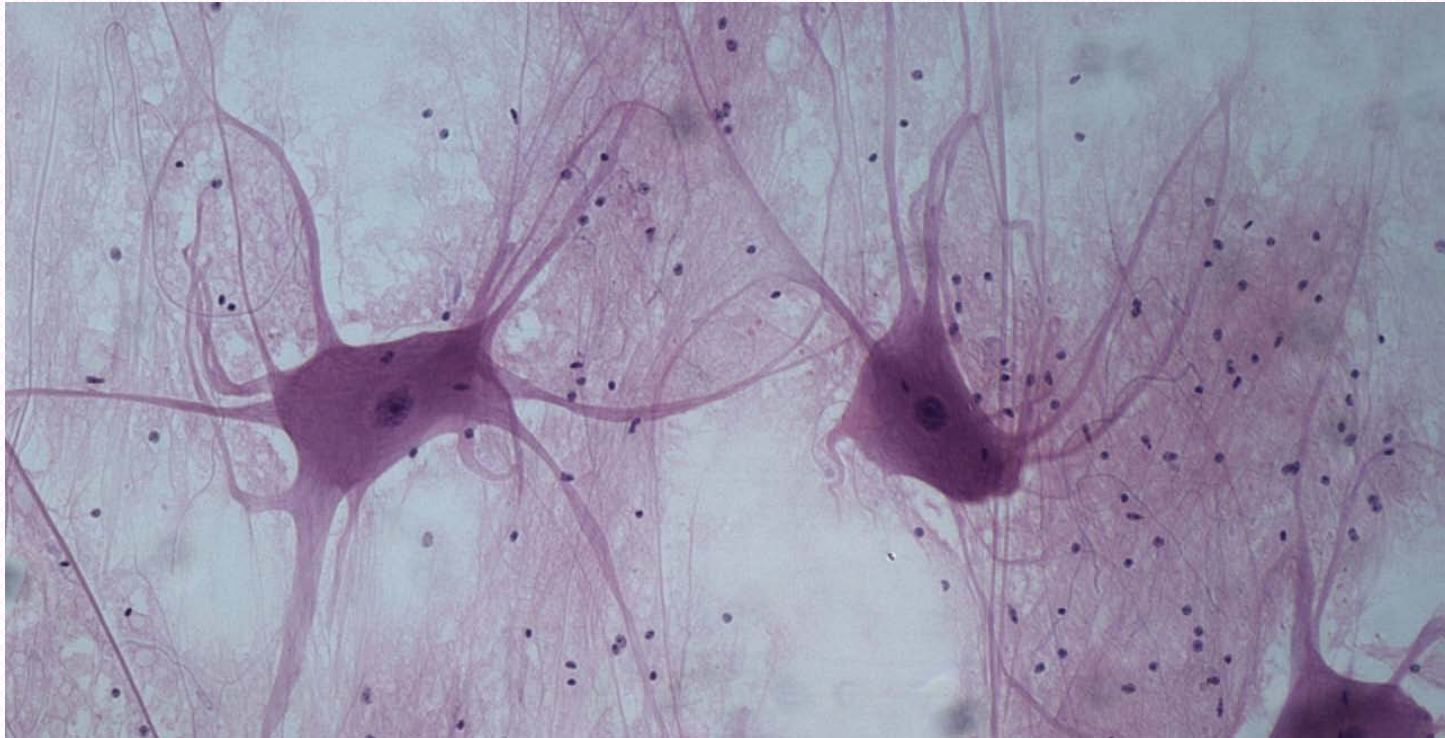
Skeletal Muscle
Striations

Identify the structure indicated.



Blood: Platelet

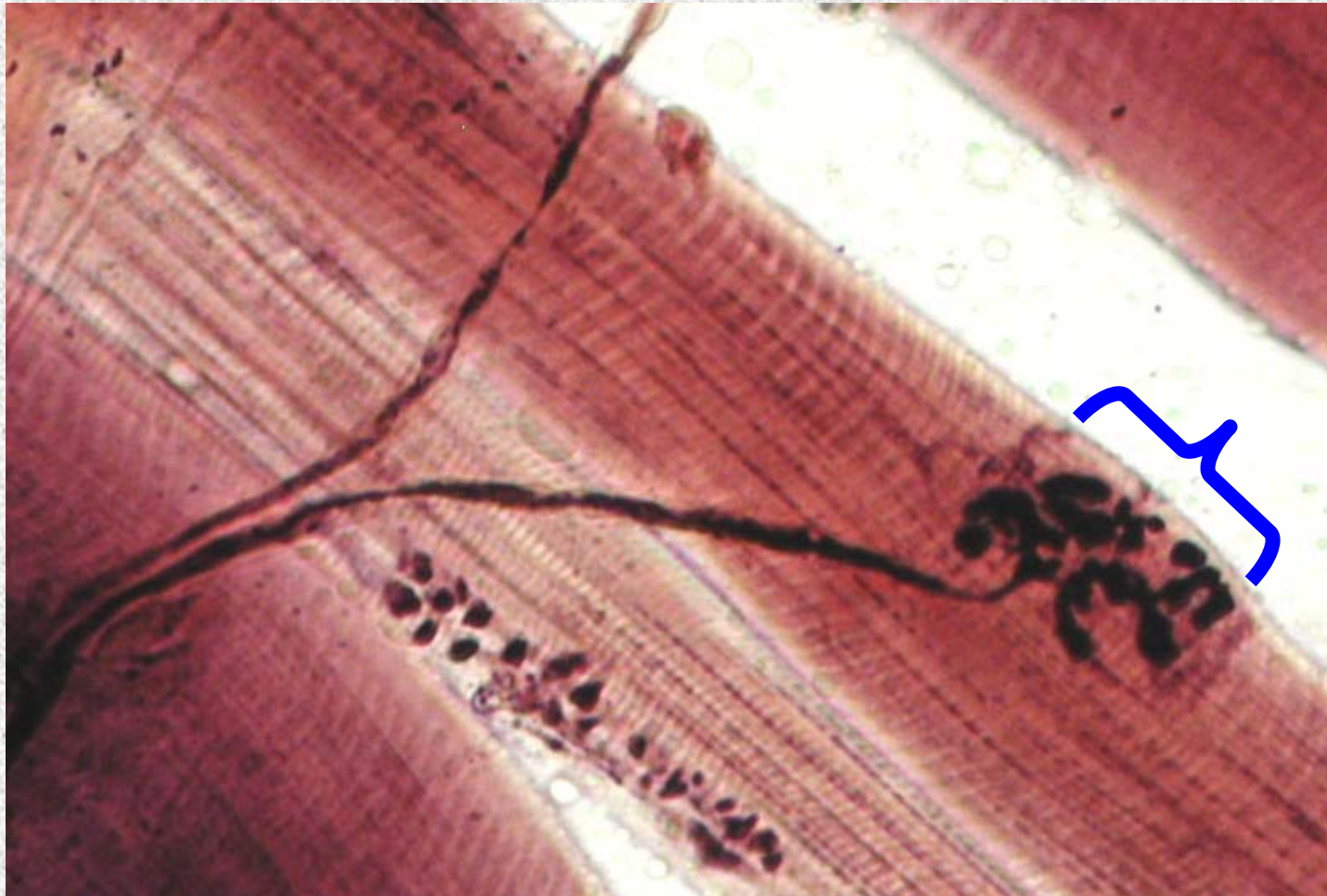Identify the tissue type and its function.



Nervous Tissue

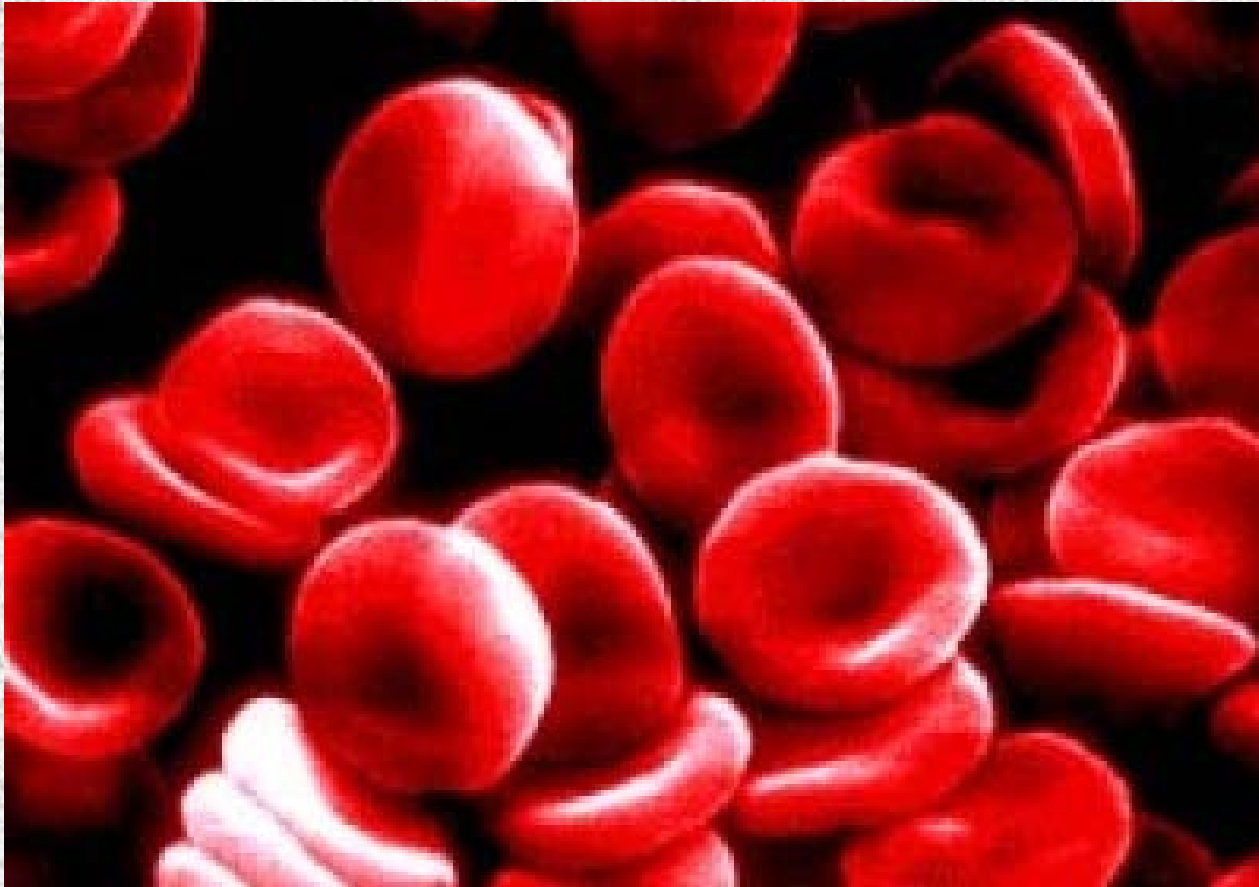
- Transport electrical signals

Identify the structure indicated.



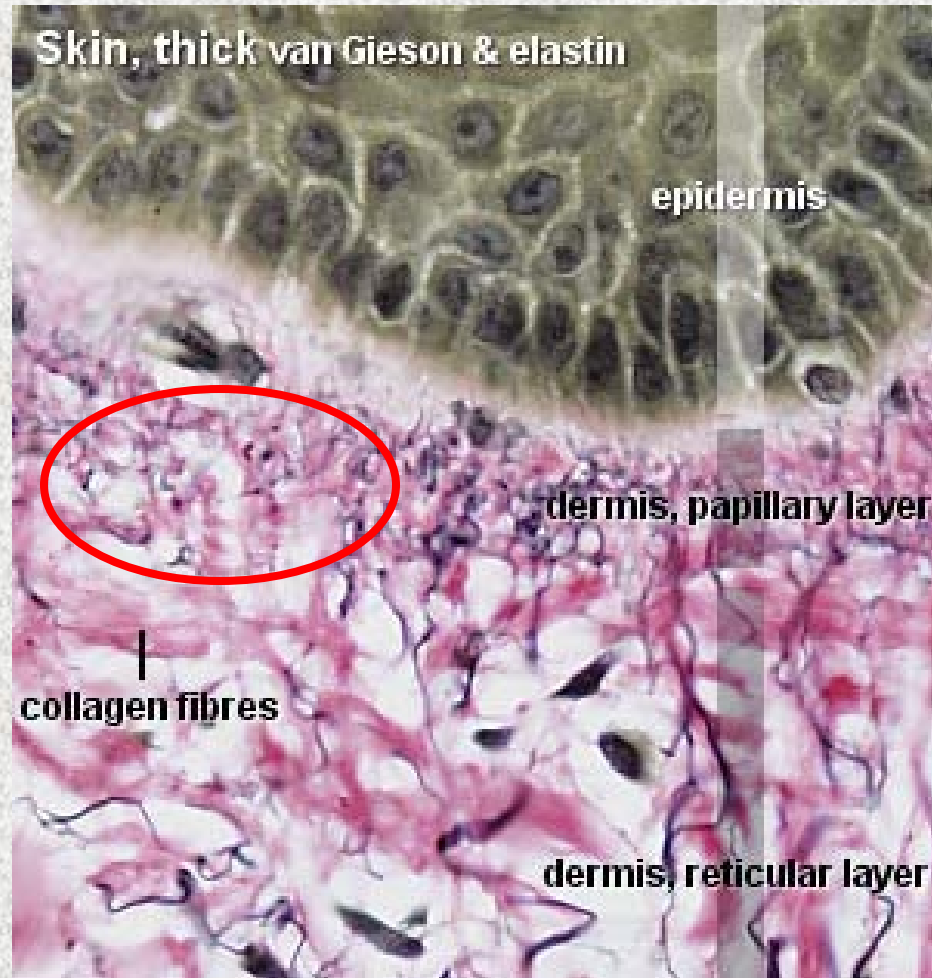Skeletal Muscle and Nervous Tissue
Motor End Plate

Identify the structure indicated.



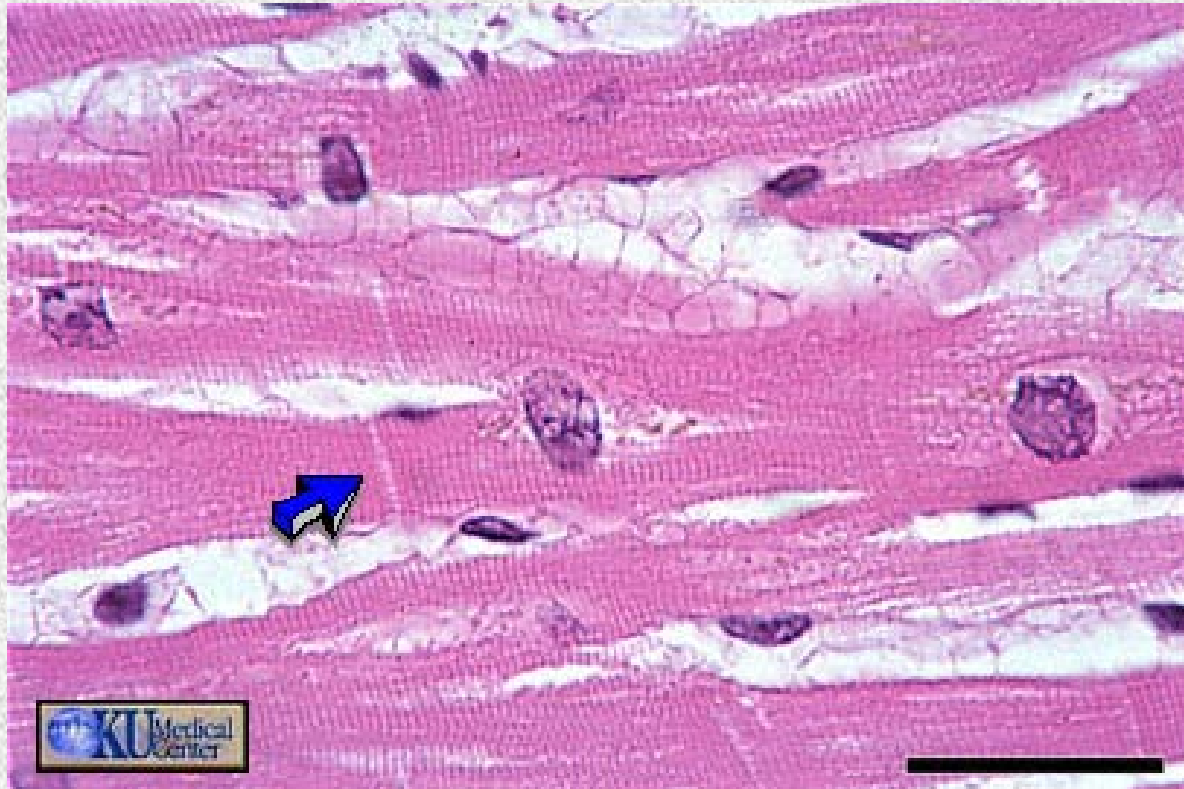
Red Blood Cells

Identify the tissue type indicated.



Areolar Connective Tissue

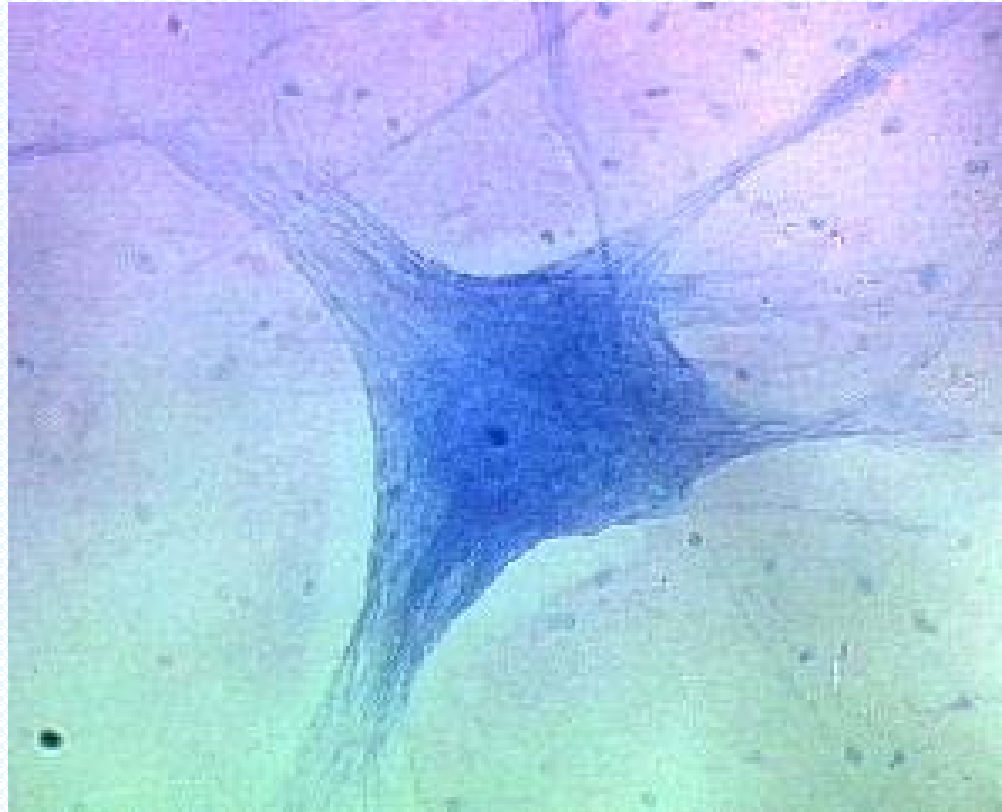
Identify the structure indicated.



Cardiac Muscle

Intercalated disc

Identify the tissue type and a location where it is found.



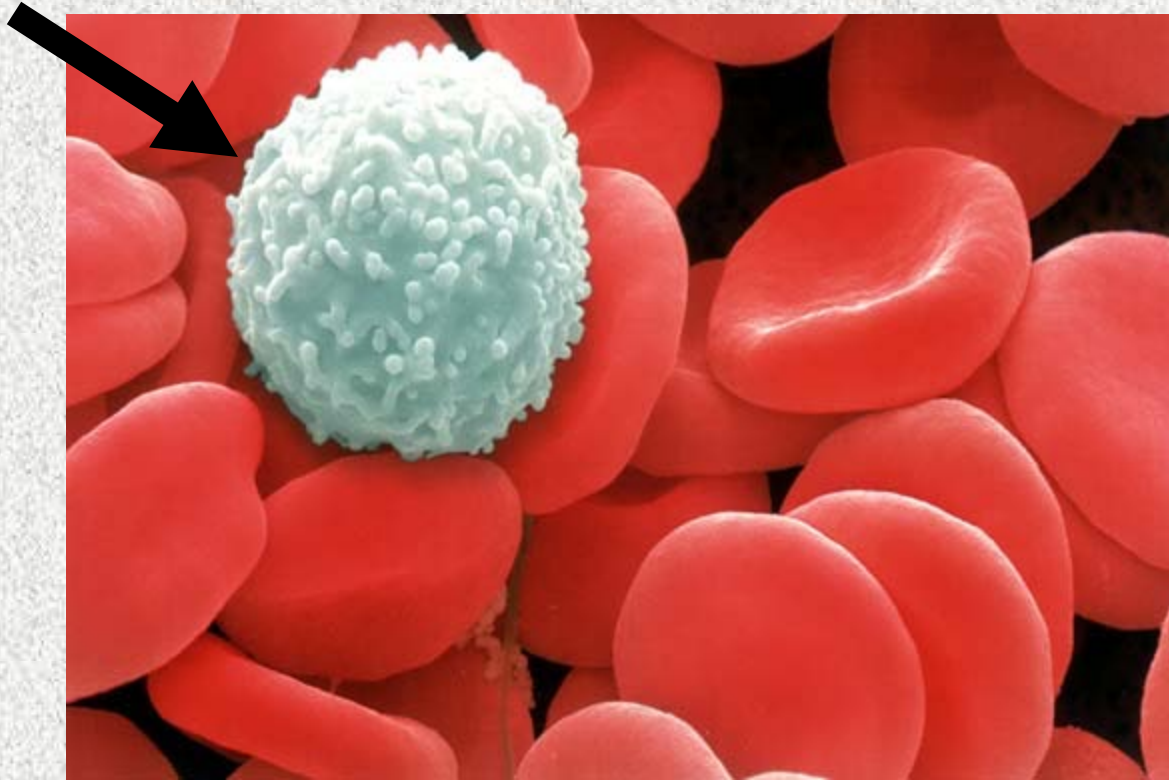
Nervous Tissue

• Brain

• Spinal Cord


• Nerves

Identify the structure indicated.



White Blood Cell

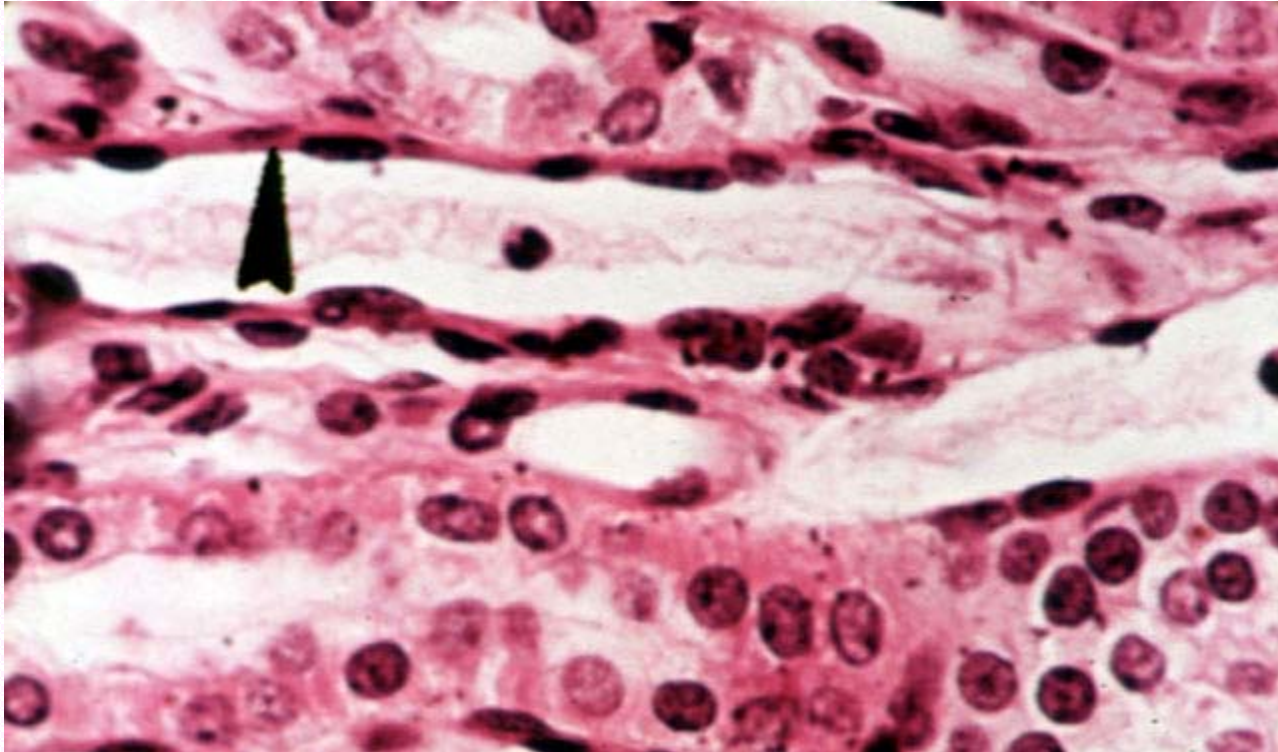
Identify the tissue type and its function.



Skeletal Muscle

- Voluntary Movement

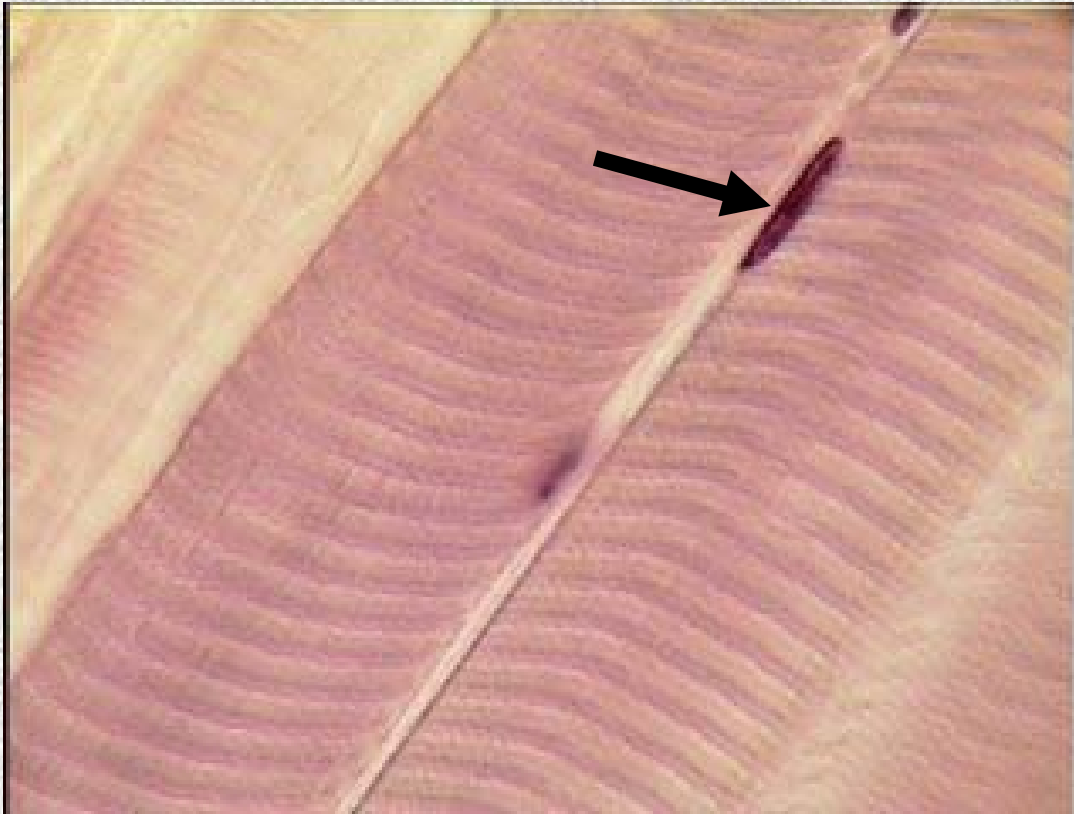
Identify the tissue type and its function.



Simple Squamous Epithelium

- Diffusion and Filtration
- Secretes lubricating substances in serosae


Identify the structure indicated.



Skeletal Muscle

Peripherally Located Nucleus

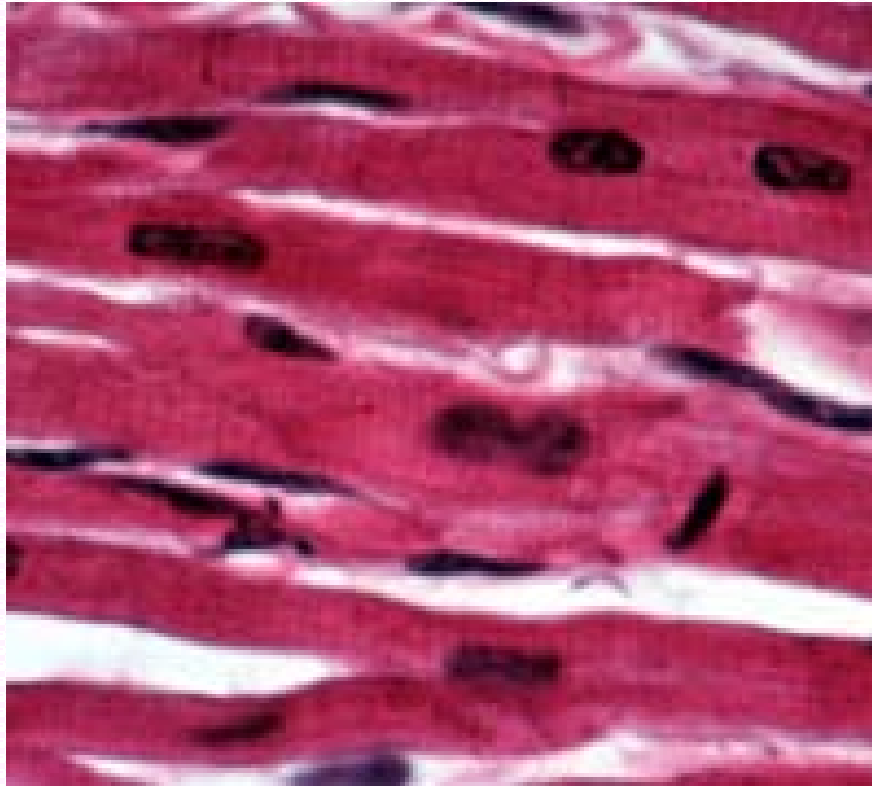
Identify the tissue type and a location where it is found.



Skeletal Muscle

- Voluntary skeletal muscles attached to bones

Identify the tissue type and its function.



Cardiac Muscle

- Contracts to propel blood through the circulatory system

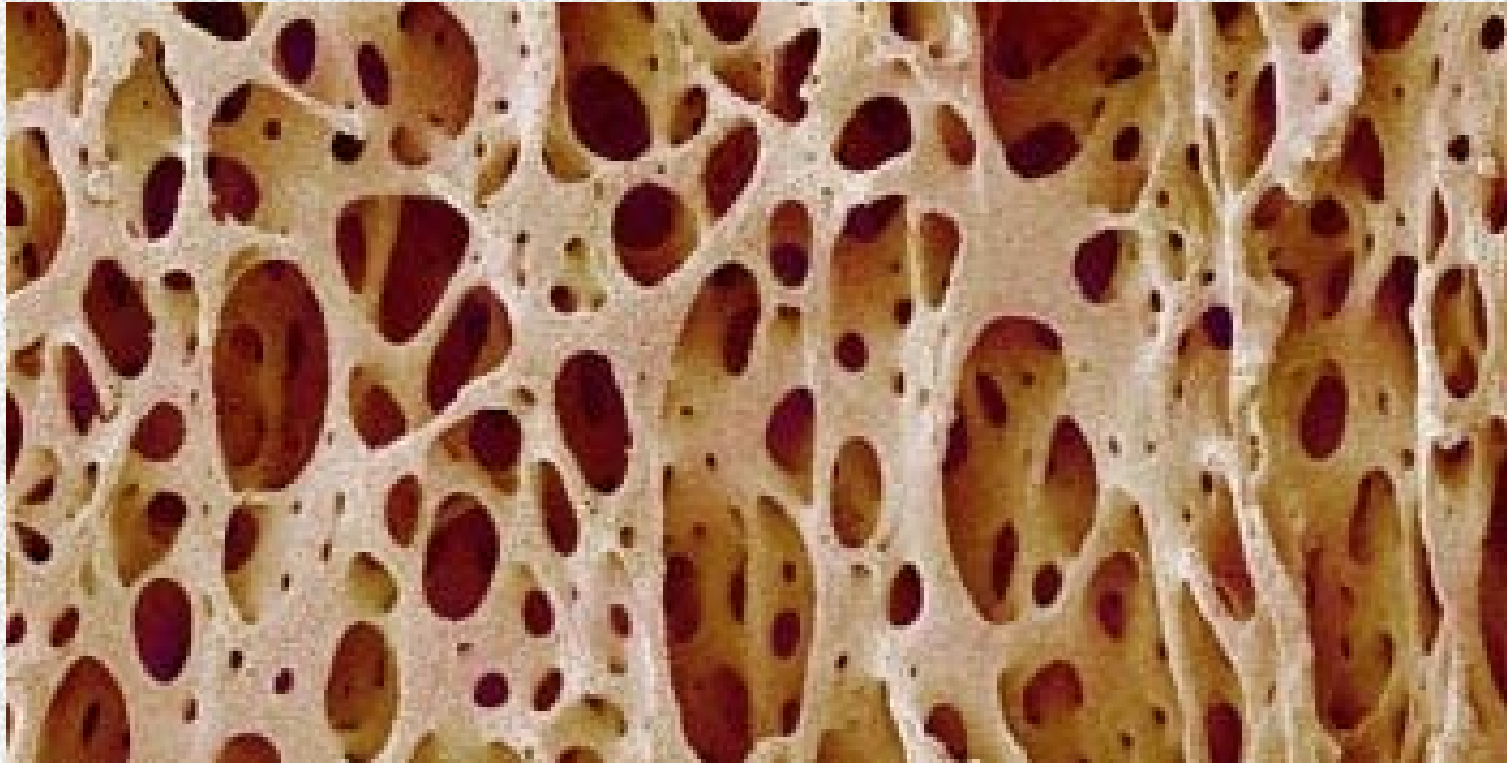
Identify the tissue type and its function.



Smooth Muscle

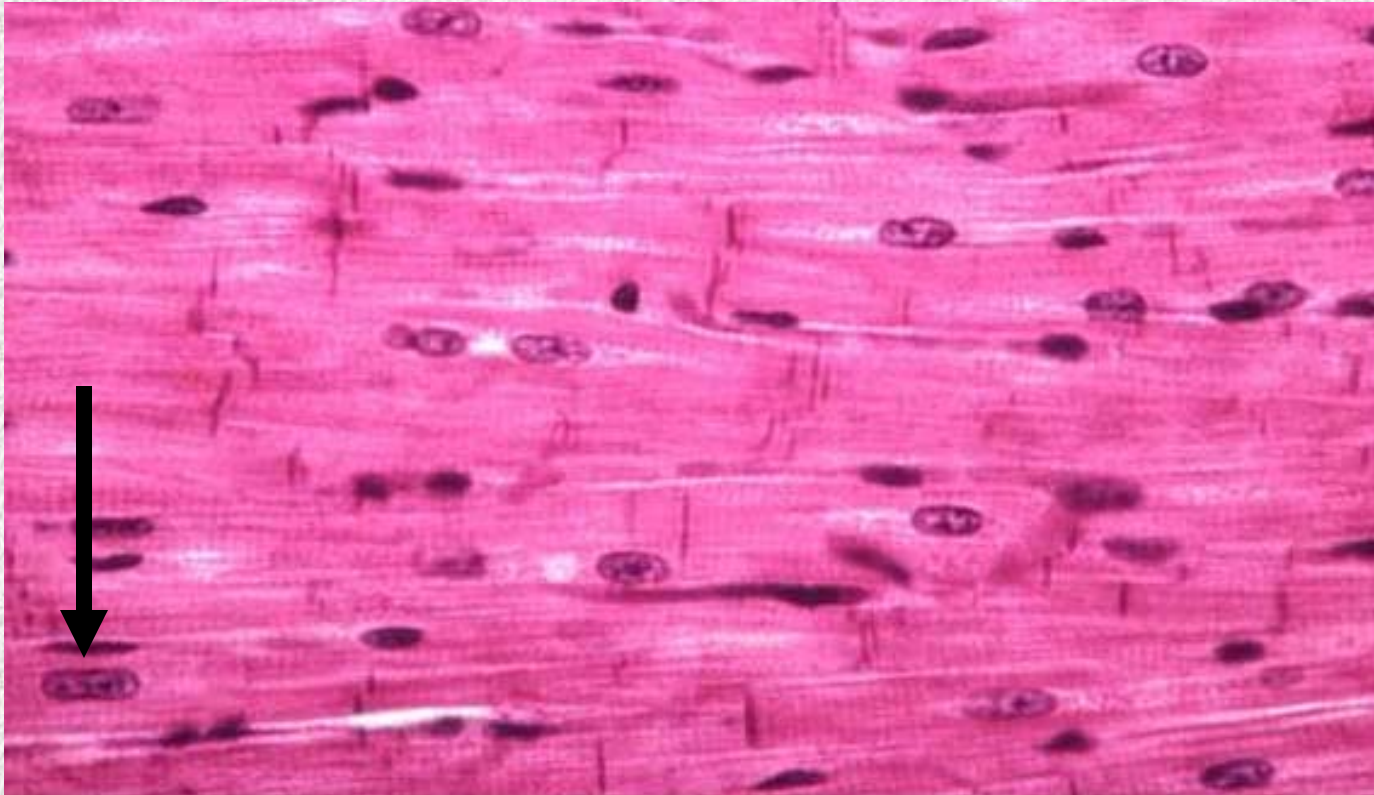
- Propels substances along internal passageways

**Identify the substance that is
located inside these holes.**



Bone Marrow (Spongy

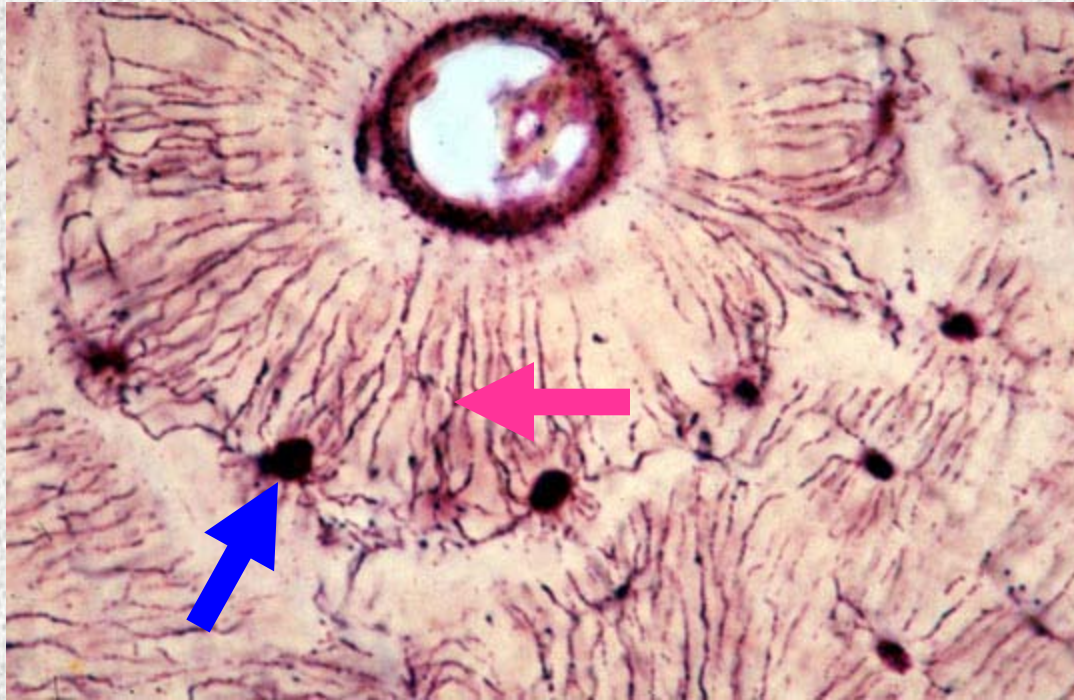
Identify the structure indicated.



Cardiac Muscle

Centrally located nucleus

Identify the structure indicated.

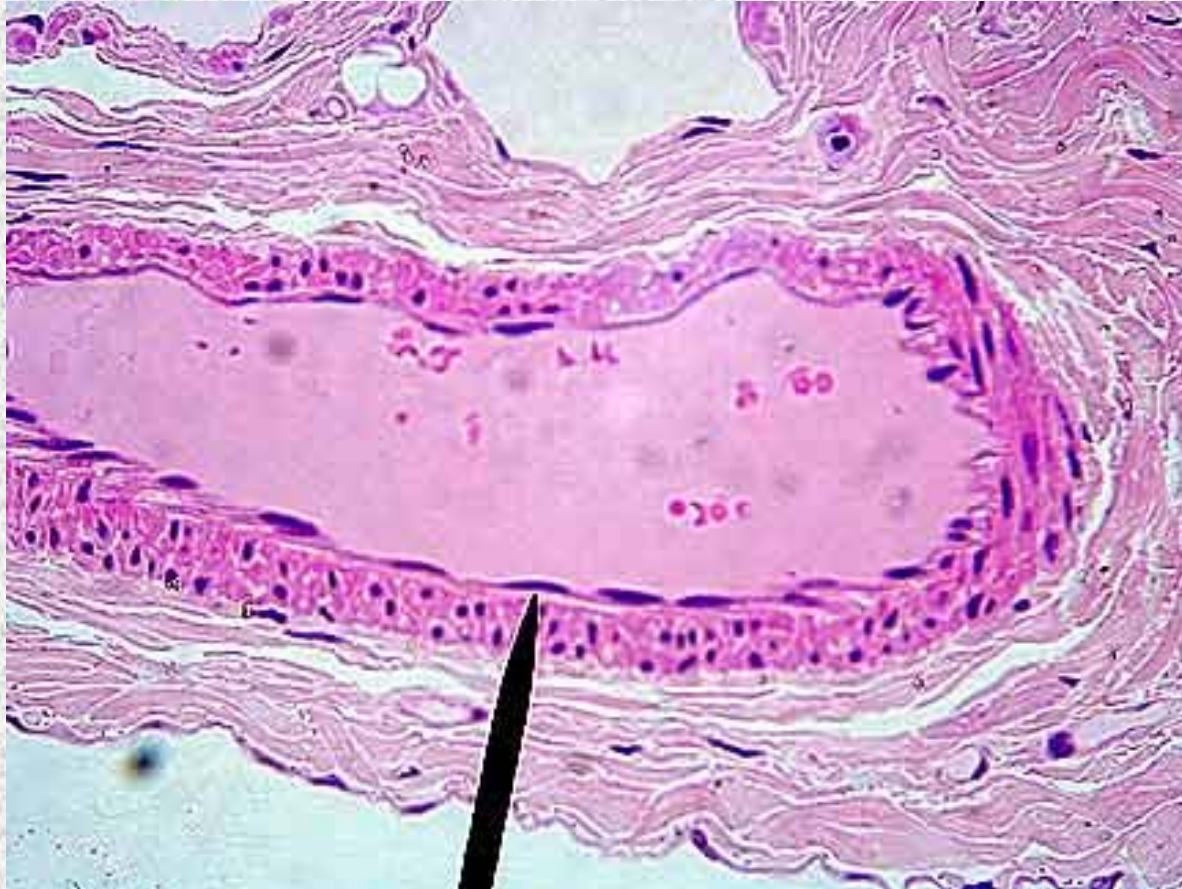


Compact Bone (Osseous Tissue)

Osteocyte in Lacunae

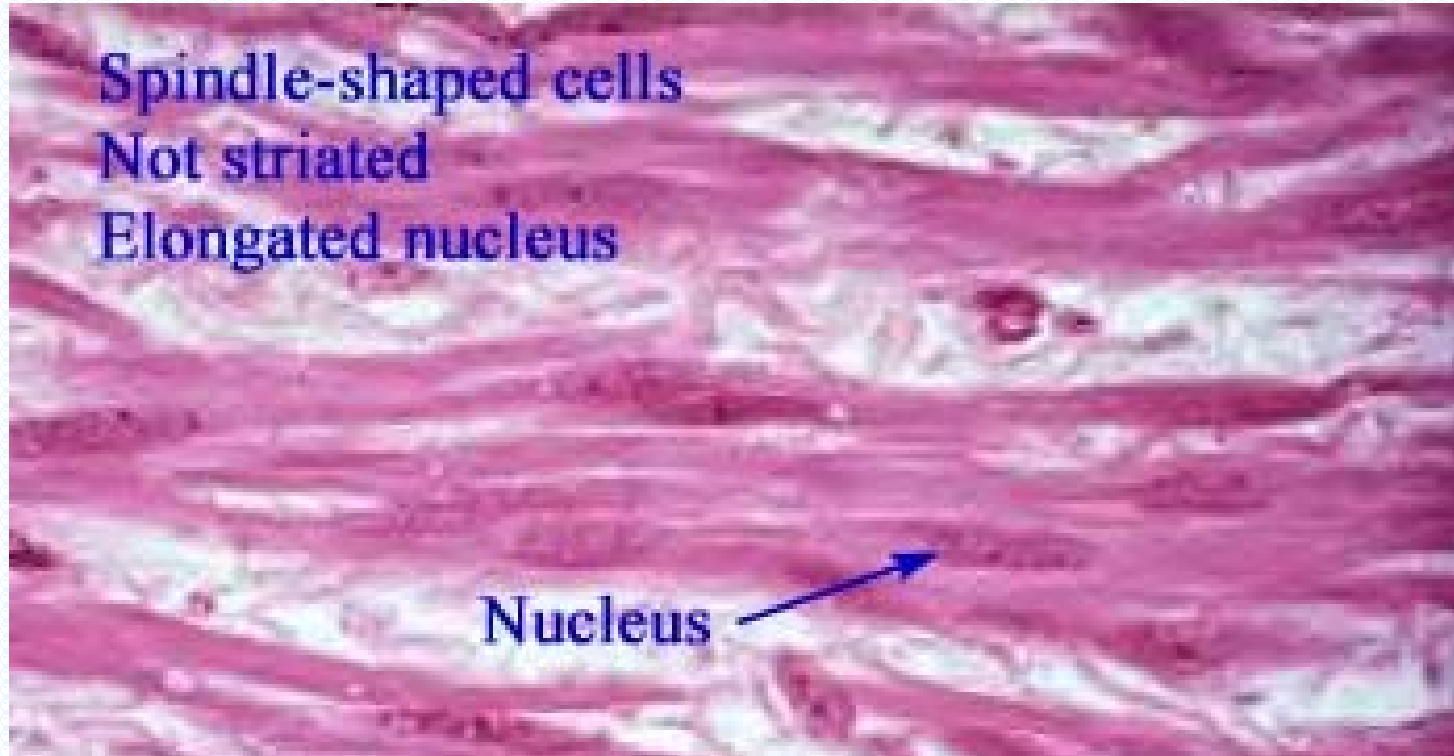
Cytoplasmic extensions in canaliculi

Identify the structure indicated.



**Simple Squamous Epithelium:
Basement membrane/Nucleus**

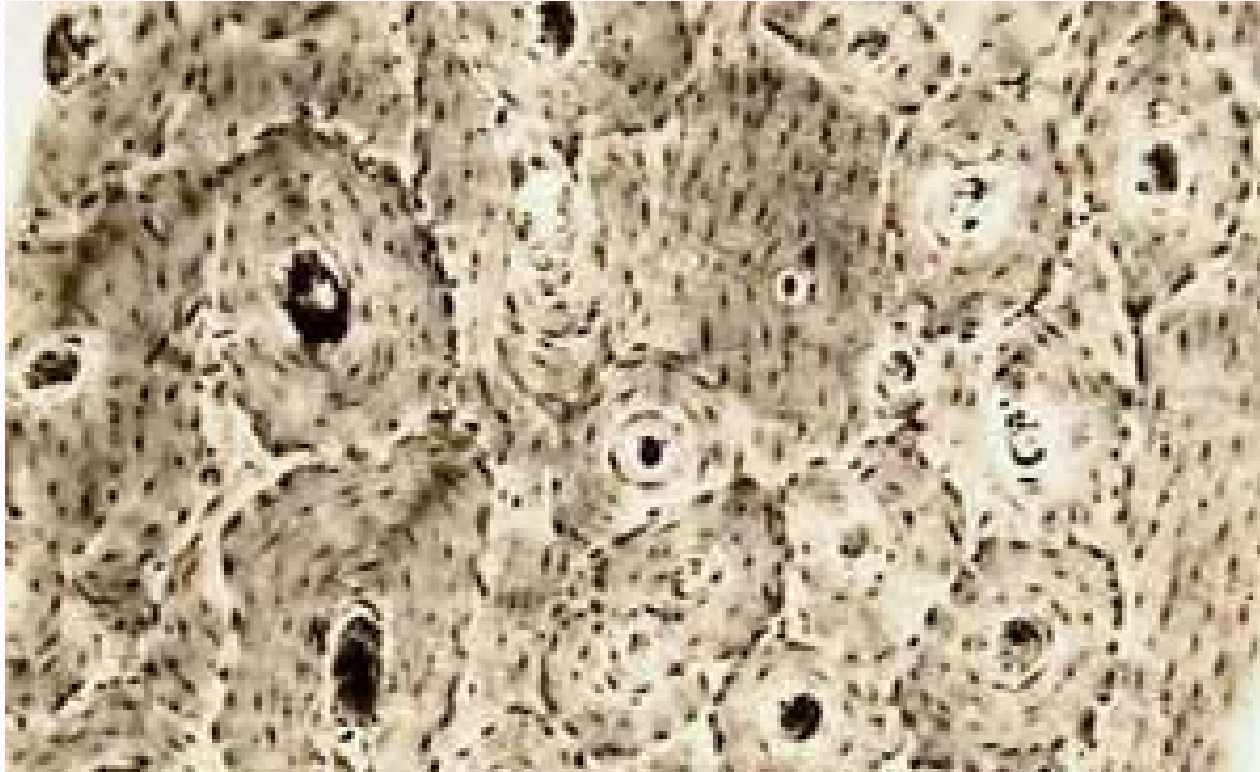
Identify the tissue type and a location where it is found.



Smooth Muscle

- Walls of hollow organs

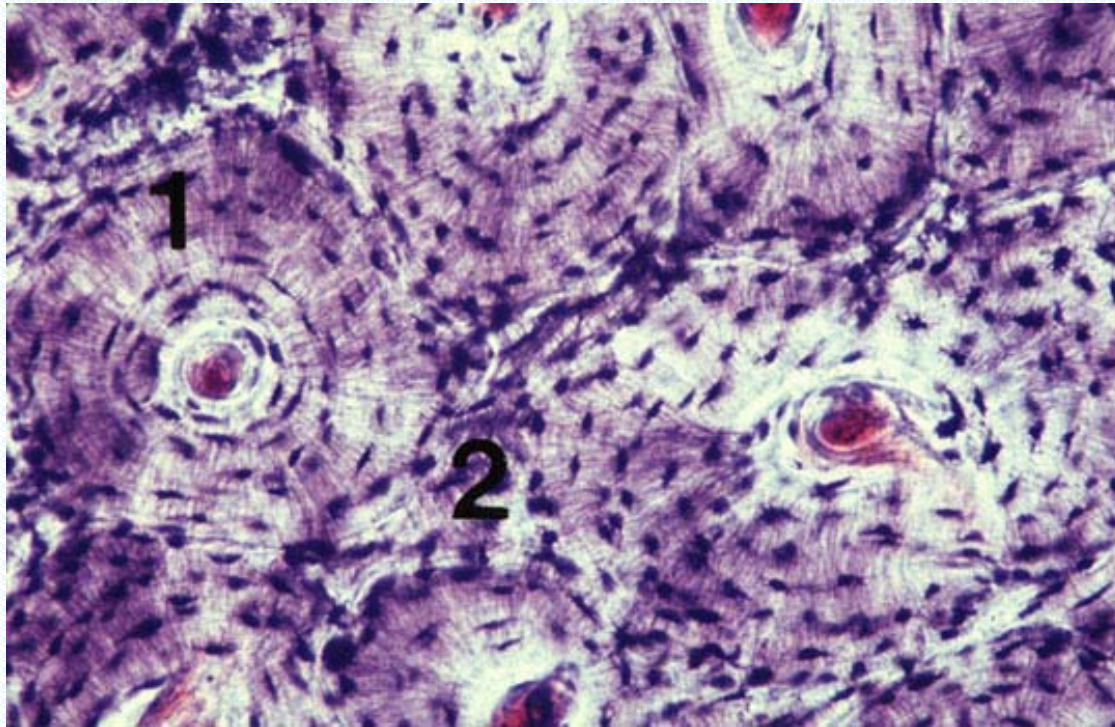
Identify the tissue type and its function.



Compact Bone (Osseous Tissue)

- Provides strength along the long axis (parallel to the osteons)
- Calcium storage

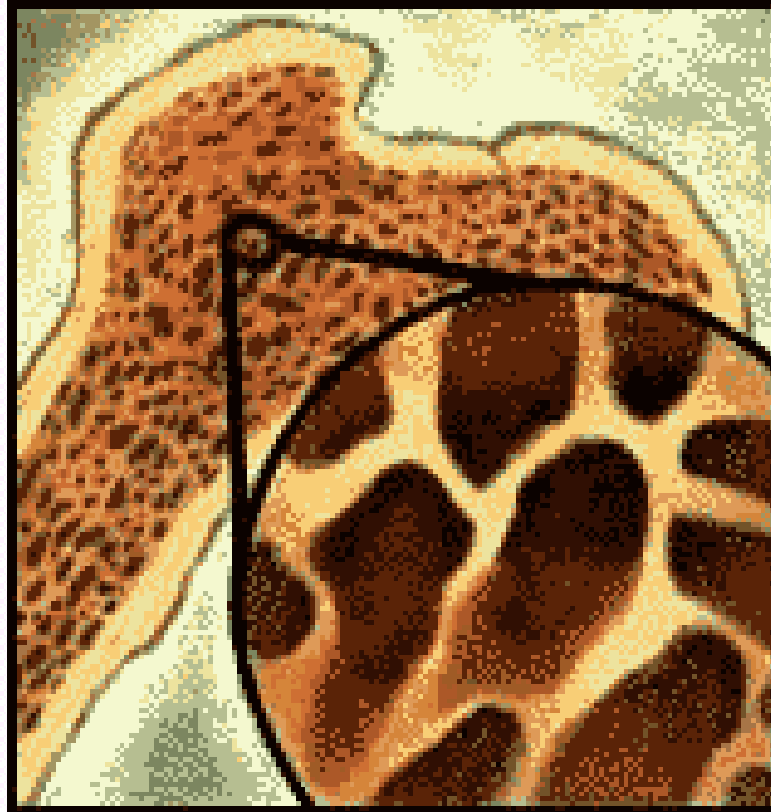
Identify the tissue type and a location where it is found.



Compact Bone (Osseous Tissue)

- The diaphysis of long bones
- The external surface of all bones

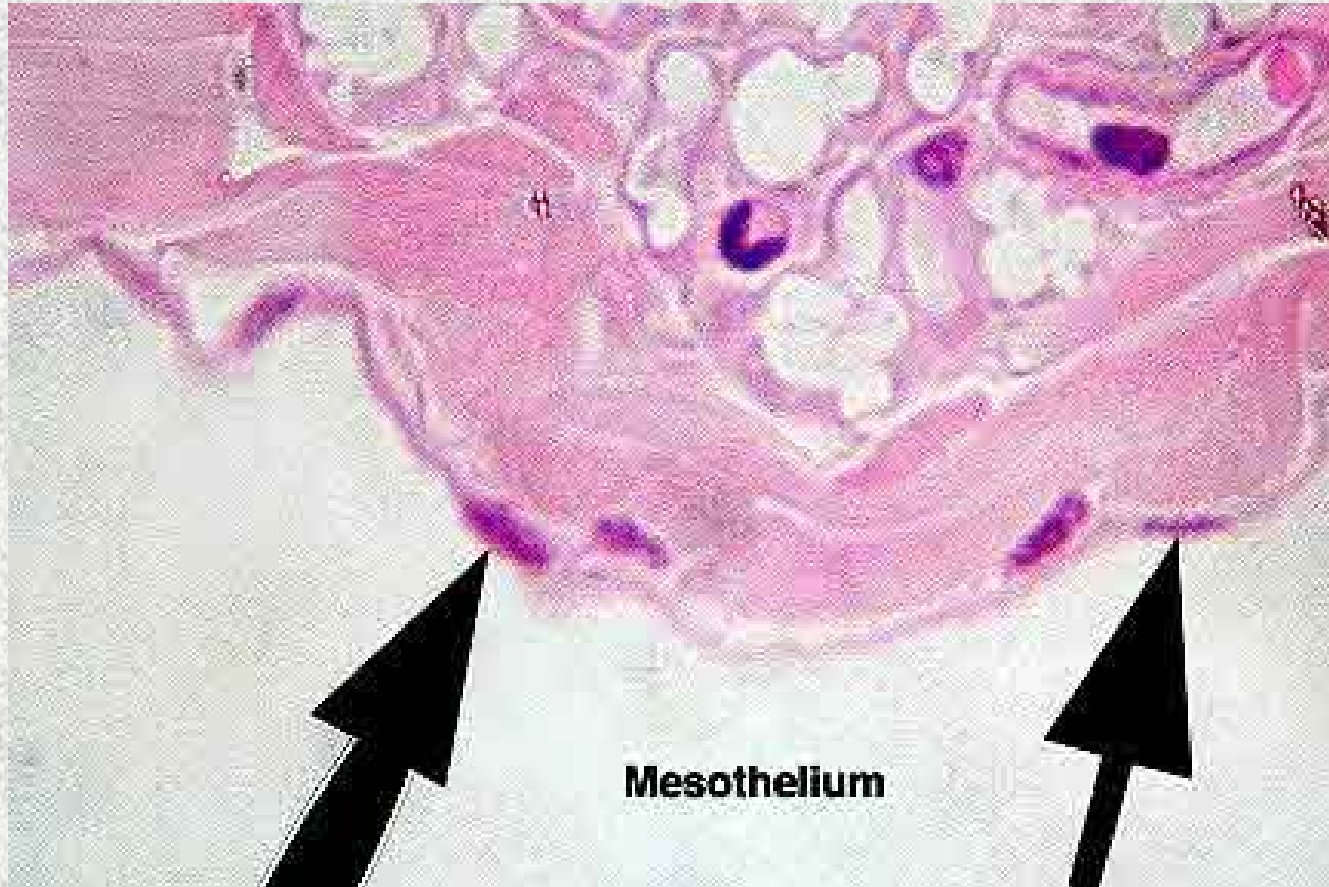
Identify the tissue type and its function.



Spongy Bone Tissue

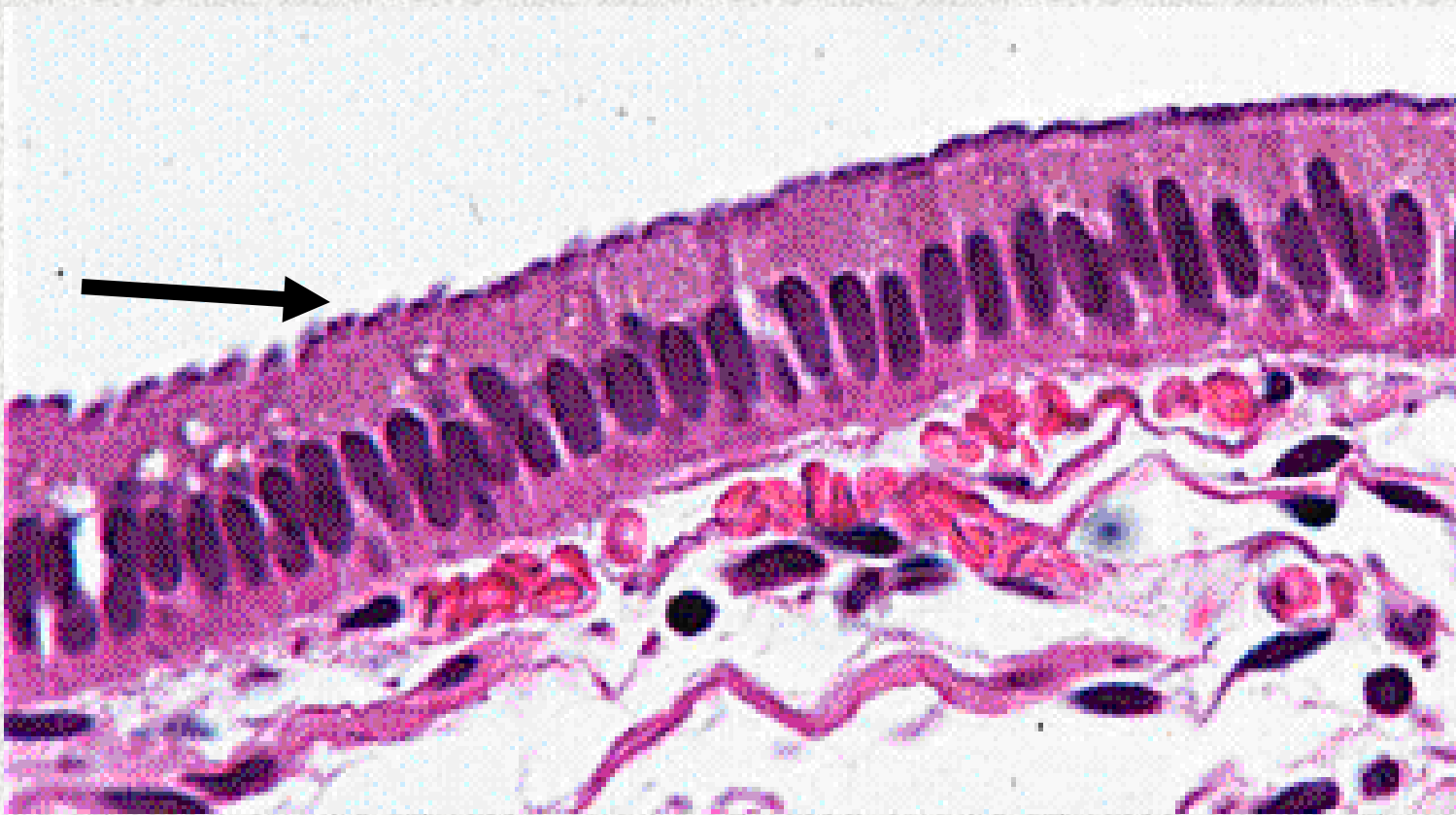- Provides considerable strength with reduced weight
- Open spaces contain bone marrow

Identify the structure indicated.



**Simple Squamous Epithelium:
Apical Surface/Nucleus**

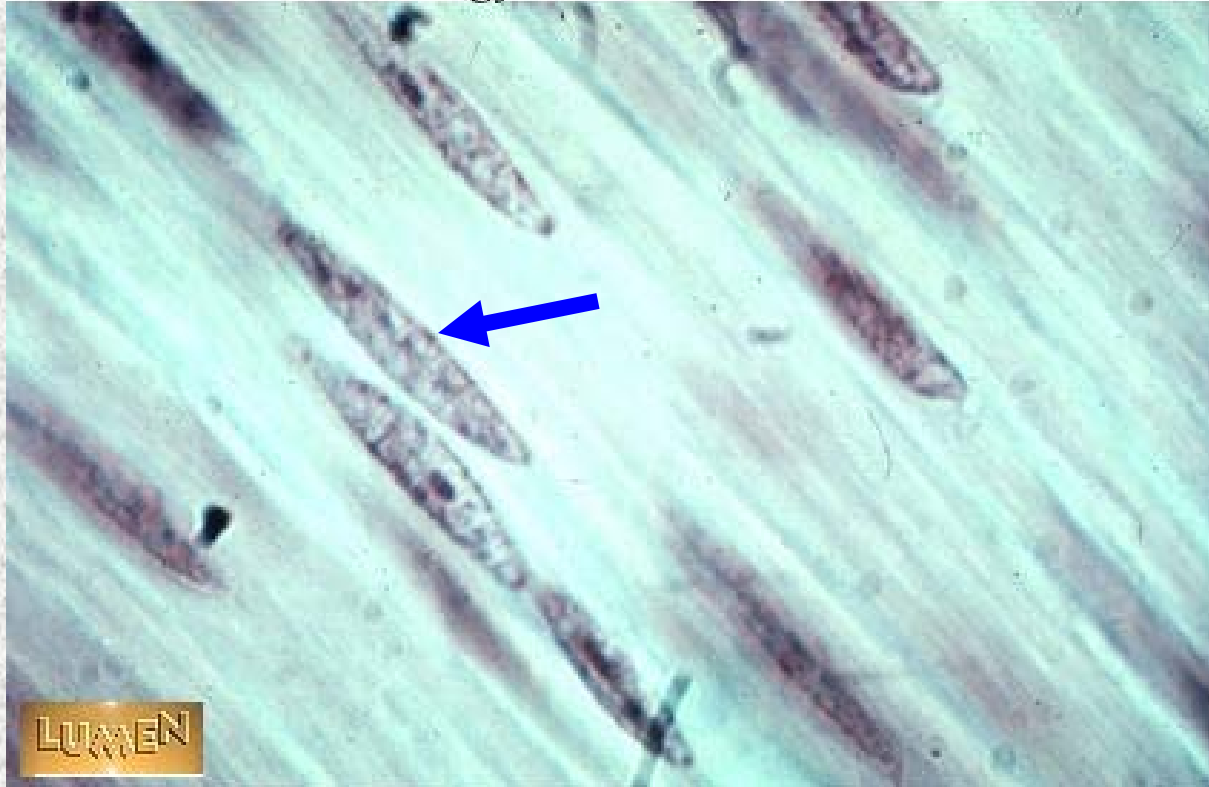
Identify the structure indicated.



Ciliated Simple Columnar Epithelium
Cilia

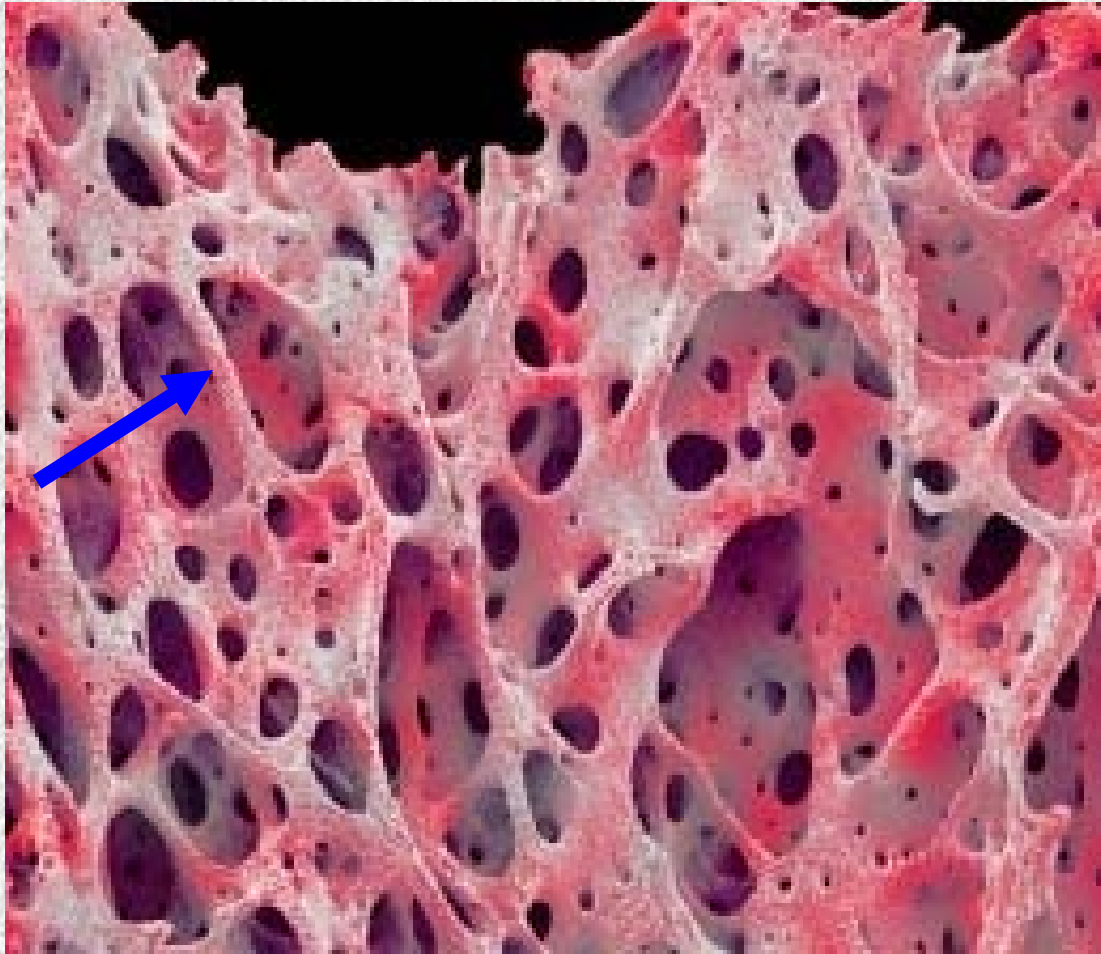
Identify the structure indicated.

Histology Lab Part 7: Slide 41



Smooth Muscle
Nucleus

Identify the structure indicated.



Trabeculae of Spongy

B